

# Negative Pressure and Phototherapy: Use of Combined and Localized Therapy to Improve Life's Quality in Parkinson disease in a Case Study

Adriana Vital Dos Santos<sup>1</sup>, Tânia Vital Dos Santos<sup>2</sup>, Kely Regina Zampieri<sup>1</sup>, Patrícia Eriko Tamae<sup>3</sup>, Antonio Eduardo de Aquino Junior<sup>1\*</sup> and Vanderlei Salvador Bagnato<sup>1</sup>

<sup>1</sup>IFSC, São Carlos Institute of Physics, Center for Optics and Photonics, University of São Paulo, Brazil

<sup>2</sup>University Martin-Luther-Halle (Saale), Germany

<sup>3</sup>Central University of São Paulo, UNICEP, São Carlos, Brazil

## Abstract

Parkinson's disease is a neurological disorder of complex alterations that occurs with its patients. This chronic and neurodegenerative disease is with an incidence above 65 years of 1% to 2% worldwide and prevalence in Brazil of 3%. The causes of the disease, mainly due to muscular atrophy and its subsequent and constant pain which make the daily life of the patients quite difficult. In this paper, we present a case report where a simultaneous combination of laser and negative pressure (Photo vacuum) is used. This application was performed in the painful regions in a sequence of sessions, allowing a stimulation of the circulation, increased muscular atrophy and better localized compression of the metabolism. The protocol was very positive with changes in the assessments made, previous and post-intervention comparisons. The positive result is more seen as a more effective test to test this protocol, as well as an organization of systematic studies that makes possible the evaluation of the clinical and mental capacity of patients with Parkinson's.

**Keywords:** Parkinson's disease; Phototherapy; Vacuum; Negative pressure

## Introduction

This disease, degenerative character, affects, in general, people over 65 years of age, covering between 1 and 2% of the world's population, while in Brazil it approaches 3%, or approximately 1.5 million Brazilians [1,2]. These data have become even more worrying with the inversion of the age pyramid in Brazil, where the population is aging on average more and more. This degeneration occurs in the neurons of the basal ganglia, specifically in the compact part of the dark substance, causing reduction or absence of dopamine production. Dopamine is the major neurotransmitter released by neurons in this region and assists in the execution of a precise and uniform motion as well as coordinated changes in body position [3].

The dopamine production system along with melanin causes neurons to undergo loss of pigmentation. In this phenomenon, it is understood that as the black substance gets brighter, the greater the dopamine loss. Associated with this loss of pigmentation occur the depletion of the neurotransmitter dopamine, and reducing the activity of the cerebral cortex motor areas, triggering the decrease of voluntary movements [4,5]. Dopamine released into the caudate nucleus and into the putamen is an inhibitory neurotransmitter, so the destruction of capacity to produce dopamine in neurons in the Parkinsonian patient's would theoretically allow the caudate nucleus and putamen to become intense, active, and possibly cause continuous outflow from excitatory signals to the cortex-spinal motor control system. These signals could intensely excite many or all of the body's muscles, thus leading to stiffness. Some of the feedback circuits could easily oscillate due to the considerable gain of the feedback loop, after its inhibition loss, leading to the Parkinson's disease characteristic tremor [6].

The connection of the cerebral cortex to the base nuclei and thalamus in relation to the motor function occurs through two direct and indirect pathways. Both influence the movement through the modulation of the inhibitory activity of the internal pallidum on the thalamus. In Parkinson's disease, decreased dopamine uptake will cause less inhibition of the inner pallidum in the direct pathway, resulting

in increased inhibition of the thalamus. In the indirect pathway, the decrease in dopamine will cause a greater inhibition of the external pallidum by the striatum and, therefore, a lower inhibition of the subthalamic nucleus, which will activate the inner pallidum more intensely, increasing the thalamic inhibition [7].

Thus, these changes in the pattern of firing by dopamine suppression, establish the motor cortex activation reduction, and possibly suppression of the muscle tone inhibitory system and inhibition of the locomotion command system [8]. Such changes justify the appearance of clinical signs of Parkinson's disease, which include resting tremor, bradykinesia consisting of impaired range and speed of movement, kinesis that corresponds to impairment at movement initiation. With this, muscle stiffness and postural instability consisting in balance deficiency, with a high risk of falls are also common aspects [9]. The quality of life perception tends to be worse due to motor deficits, restrictions of daily activities and depression caused by the frustration in the simple day-by-day tasks [10].

Non-motor symptoms, such as pain, in Parkinson's disease patients are very frequent, leading to change in the quality of life and degree of autonomy of these individuals. In a study carried out in 2010 with 159 patients with Parkinson's disease, pain was the most frequently reported non-motor symptom, affecting 72.3% of patients [11]. Stress caused by sustained muscle contraction and muscle spasm may induce the release

**\*Corresponding author:** Antonio Eduardo de Aquino Junior, São Carlos Institute of Physics, Center for Optics and Photonics, University of São Paulo (USP), P.O. Box 369, 13560-970, São Carlos, SP, Brazil, Tel: +55-016-3373 9810; E-mail: [antoniodeaquinojr@gmail.com](mailto:antoniodeaquinojr@gmail.com)

**Received** June 19, 2019; **Accepted** July 09, 2019; **Published** July 16, 2019

**Citation:** Santos AVD, Santos TVD, Zampieri KR, Tamae PE, de Aquino Junior AE, et al. (2019) Negative Pressure and Phototherapy: Use of Combined and Localized Therapy to Improve Life's Quality in Parkinson disease in a Case Study. J Alzheimers Dis Parkinsonism 9: 471.

**Copyright:** © 2019 Santos AVD, et al. This is an open-access article distributed under the terms of the Creative Commons Attribution License, which permits unrestricted use, distribution, and reproduction in any medium, provided the original author and source are credited.

of substances that sensitize the nociceptors and generate localized pain. This pain, conjugated with contractions, may result in circulatory deficits and nutritional impairment, as well as affect muscular functional performance [12]. Muscle rigidity is responsible for the muscular tension centered mainly at the level of the vertebral column and the root of the limbs [13]. Some studies suggest that musculoskeletal pain seems to be related to the presence of muscular rigidity and kinesis and that typically affect the muscles of the neck, arm, paraspinal or posterior leg region [14]. Muscle spasms can also result from an indirect effect compressing blood vessels and leading to ischemia. It also increases the intensity of muscle tissue metabolism, making relative ischemia even greater and creating ideal conditions for the release of pain-inducing chemicals [6]. Increased energy consumption, under conditions of ischemia resulting from extrinsic compression of the capillaries by muscle and venous stasis, can result in lower nutrient intake and cause an imbalance between necessary cell nutrients. Consequently the ATP synthesis, results in impairment of active Calcium ions ( $Ca^{2+}$ ) reuptake by the pump in the endoplasmic reticulum, a phenomenon necessary for muscle relaxation [12].

One of the causes suggested for pain during ischemia is the accumulation of large amount of lactic acid in the tissues, formed because of the anaerobic metabolism. Other chemical agents, such as bradykinin and proteolytic enzymes, are also likely to be formed in tissues because of cell damage, and that these agents, along with lactic acid, stimulate nerve endings for extreme pain [6].

In this situation, one of the common resources used as therapeutics for the discomfort is the use of anti-inflammatory and pain reliever. There is however, equivalent action of analgesia and anti-inflammatory reaction, produced by phototherapy. Phototherapy is the treatment by light (especially laser) well established in the health therapeutical practice and acts on the cellular level as a help for the cellular energy metabolism. The influence of light stimulation in the respiratory chain of the mitochondria is proved, increasing energy synthesis (ATP) and allowing several therapeutic effects. In special when the homeostasis is altered with induced mechanical stress, by negative pressure therapy, the created metabolic demand produces the ideal conditions for laser to act. This occurs due to various stimuli to the body, such as energy, metabolic changes, temperature and blood circulation [15].

There are two basic effects after the application of negative pressure, such as the improvement of blood quality, by the release of substances caused by suction and the improvement of blood circulation, also contributing for the resolution of pain, muscle relaxation and the balance of body functions [16].

In this context, phototherapy associated simultaneously with negative pressure, interacts with physiological responses, more rapidly returns cellular, and tissue homeostasis to the body, potentializing and accelerating the therapeutic effects of tissue, muscle, bone and peripheral regeneration, as well as increased microcirculation, the synthesis of collagen and the anti-inflammatory action with analgesia. The combined use of negative pressure therapy simultaneously with phototherapy may bring benefits in terms of improved muscle stiffness and pain, since the combined therapy interacts with physiological responses and more rapidly returns cellular and tissue homeostasis to the body [16]. Such effects of laser therapy and negative pressure combination are the necessary ingredients to improve many aspects associated with Parkinson's disease.

Thus, we decided to test, in a clinical case, the combined effect of the phototherapy with negative pressure in Parkinson's disease.

The present study aims to evaluate the combined and localized use of Negative Pressure and Phototherapy, in the improvement of conditions caused by Parkinson's disease through a case report. A full clinical study is being prepared. Nevertheless, the case study was essential for the study design. The result was so positive and surprising that motivate the case report.

## Case Presentation

This report is characterized by being a case study, composed of one male gender patient, 70-years-old, with Parkinson's disease. The symptomatology was composed of muscular pain in the cervical region, dorsal trunk and left arm, and presence of left unilateral severe resting tremor. The patient is submitted to the drug treatment with Levodopa and Cannabidiol, associated to the accomplishment of physical activity, three times a week. A physiotherapeutic group performed data collection and attendance during the month of January 2019 at a private Clinic with the presence of other specialists. The instruments used in the data collection were evaluation form, containing questions about personal data and characteristics of the subject studied; Visual Analog Scale; Quality of Life Questionnaire on Parkinson's disease and modified Hoehn and Yahr Scale [17]. Regarding the procedures, an interview was made to collect personal data and sample characteristics. Subsequently, the Visual Analog Scale, Quality of Life Questionnaire on Parkinson's disease and Hoehn and Yahr Scale were applied. The subject's characteristics collected were age, gender, marital status, schooling, age of onset of disease, duration of disease, stage of disease and medication. The disease stage was evaluated by the modified Hoehn and Yahr Scale, scored from 0 to 5, and the higher the score, the more serious the impairment.

The researcher from the observation of the clinical picture in eight stages applies this scale: (0) for no sign of the disease; (1) for unilateral disease; (1.5) for unilateral and axial involvement; (2) for bilateral disease, without compromising the balance; (2.5) for bilateral disease with mild impairment of balance; (3) for bilateral disease of mild to moderate impairment of balance; (4) for severe disability, but able to stand and walk unassisted; and (5) for a person in a wheelchair or bedside, requiring complete help [16].

To evaluate pain intensity, the Visual Analogue Scale was used. In order to use this scale, the individual was asked about their degree of pain, 0 of which means total absence of pain and 10 the maximum level of pain that the patient can bear.

To evaluate the quality of life, the Quality of Life Questionnaire for Parkinson's disease was used an indicator of the individual's perception of physical, emotional and social health. This evaluation tool is a questionnaire with 38 questions and 2 alternative answers (yes or no). It involves issues such as physical ability, energy level, pain, emotional reactions, social isolation, and sleep quality. Each "yes" answer corresponds to one point and the smaller the total score obtained, the better the individual's perception of their quality of life.

The scale for pain assessment and the quality of life questionnaire were applied in the evaluation and after the six sessions of the treatment protocol application. Two sessions per week were performed, with duration of 30 minutes, totaling 6 sessions.

The subject was submitted to the application of a combined phototherapy and negative pressure, using the device Photo Vacuum (produced by MMO- São Carlos- SP- Brazil) as presented in Figure 1. The therapy protocol corresponds to the application in the dorsal trunk and cervical spine bilaterally and in the left arm, covering the following

muscles: Muscle triceps muscle, semi-spinal muscle, multifidus, rotator muscles, interspinal muscles, intertransverse muscles, trapezius muscle, major and minor rhomboid muscle, latus posterior muscle and scapula-lifting muscle. The equipment was adjusted to the following parameters: pulsed mode, MP7, two wavelengths connected (3 red 660 nm and 3 infrared 808 nm), time 20 minutes being five minutes per area, making the sliding movement with the medium suction cup, at the pressure of 200 mmHg (Figure 2).

## Results

The case study was carried out with a 70-year-old male gender patient with Parkinson's disease. Evaluated to be in the early stages of the disease, stage 3 with a score of 1.5. According to the Hoehn-Yarh modified scale, presenting rest tremor, in the upper and lower limbs with left unilateral involvement and altered posture. Figure 3 shows the data collected on pain intensity using the Visual Analogue Scale, before and after six sessions of the treatment protocol application with Photon Vacuum therapy. Comparison of the pre and post-application pain intensity of the protocol showed that in the pre-application the pain was characterized by the subject as moderate grade 6 and after six protocol applications pain was characterized as mild grade 1, evidencing considerable pain improvement (Figure 3).




Figure 1: Photon vacuum equipment that combines laser therapy in both wavelengths (660 nm and 808 nm) with negative pressure.

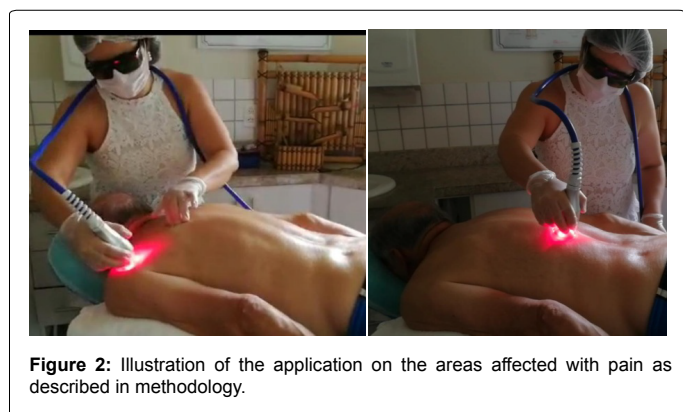

Figure 2: Illustration of the application on the areas affected with pain as described in methodology.

Table 1 shows the perception of the quality of life of the individual under study, evaluated by the Nottingham Health Profile (PSN) on issues faced on a daily basis. In the five categories, each item had a response, whose sum of YES, pre- and post-treatment, shows improvement in the quality of life perception, and can be related to reduction of muscle pain.

Table 2 shows the percentage of improvement in each category for the after procedure-Intervention Quality of Life Questionnaire. Comparing before and after intervention results, there were significant percentage differences in all categories

## Discussion

The present study evaluated the combined and localized use of negative pressure and localized phototherapy, in the improvement of conditions caused by Parkinson's disease. The patient assessed, is in the early stages of the disease, in which there is a unilateral manifestation of the symptoms, where, the subject can live independently. The

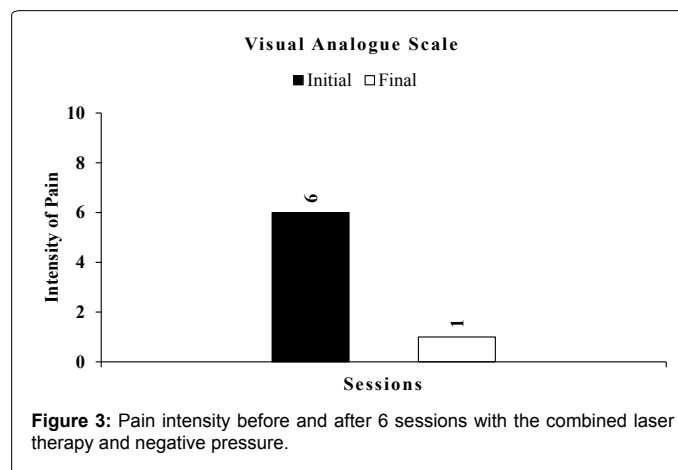


Figure 3: Pain intensity before and after 6 sessions with the combined laser therapy and negative pressure.

Question	Before treatment	After treatment
I feel pain at night. The pain I feel is unpalatable	Yes	No
I feel pain when changing body position	Yes	No
I feel pain when walking	Yes	No
I feel pain when standing up	Yes	No
I feel pain constantly	Yes	No
I feel pain when going up or down stairs	Yes	Yes
I feel pain when sitting in the chair	No	No

Responses defined within the concept of pre-treatment and post-treatment.

Table 1: Questions for life quality following Nottingham Health Profile - Category PAIN.

Categories	Before	After	Perceptual difference (%)
Pain	6	1	83.33
Emotional reactions	6	0	100
Sleep	3	0	100
Social interaction	1	0	100
Physical skills	10	1	90
Energy level	3	0	100

Responses defined within the concept of pre-treatment and post-treatment, on a scale of 0 to 10.

Table 2: Percentage of improvement in each category after the treatment protocol application with photo vacuum therapy.

study demonstrated that after the intervention with the treatment protocol using combined phototherapy and negative pressure therapy simultaneously using the commercial device Photo Vacuum, the subject obtained a reduction in the intensity of muscular pain, from moderate pre-intervention to mild post-intervention, analyzed through the Visual Analogue Scale. Muscle pain improvement was also evident in the post-intervention and quality of life, as well as the categories of physical abilities, sleep and emotional reactions, improving the quality of life of this subject. The results obtained show that the physical condition is important and affects the daily life of patients with Parkinson's disease, which is in agreement with Lemke et al. [10]. The quality of life perception tends to be worse due to motor deficits, daily activity restrictions, and depression. In fact, the chronicity of muscular pain is associated with important functional limitations, which imply limitations in daily living activities. Stress caused by sustained muscle contraction and muscle spasm can induce the release of substances that sensitize the nociceptors and generate localized pain, which may result in circulatory deficits and nutritional impairment, as well as affect muscular functional performance [12].

The pain reduction evidenced in the present study is possibly due to the physiological effects of combined negative pressure therapy with phototherapy in muscle tissue. According to Cunha, there are two basic effects after the application of negative pressure, such as the improvement of blood quality by the release of substances caused by suction and the improvement of blood circulation, also waiting for the resolution of pain, muscle relaxation and the body functions balance [15]. The physiological effects of negative pressure on tissue homeostasis are potentiated with the anti-inflammatory action of phototherapy. Observing these benefits, the subject reported improvement of pain in the dorsal region of the trunk, cervical spine and left upper limb, since the first applications of the protocol, being reduced until the sixth application, characterizing it as of light intensity. In addition, the absence of the resting tremor during the application of the protocol was observed, being evident after the end of the application, remaining at rest. Based on this positive result for a controlled case, a full study is in preparation. Nevertheless, due to the importance to apply technique that make a life of Parkinson's disease better, the case report looks of fundamental importance.

## Conclusion

We hypothesize that in the present study, the combined use of negative pressure and localized phototherapy contributed positively to the reduction of muscle pain, to the improvement of the local blood circulation, consequently enabling a better blood supply to the cellular metabolism and consequently improvement of the physical abilities, helping in the better quality of life of parkinsonians.

## Acknowledgements

All the authors thank the support of the CEPID/FAPESP program as well as the INCT/CNPq program. AVS thanks support from MMO- São- Carlos- SP- Brazil for supporting and viability of the device for the study.

## References

1. Dowding CH, Shenton CL, Salek SS (2006) A review of the health-related quality of life and economic impact of Parkinson's Disease. *Drugs Aging* 23: 693-721.
2. Paula RF, Teixeira-Salmela LF, Faria CDCM, Brito PR, Cardoso F (2006) Impact of an exercise program on physical, emotional, and social aspects of quality of life of individuals with Parkinson's disease. *Mov Disor* 21: 1073-1077.
3. <https://periodicos.pucpr.br/index.php/fisio/article/view/19033/18381>
4. Teive HAG (2005) Etiopathogenesis of Parkinson's disease. *Ver Neurocienc* 13: 201-214.
5. Pieruccini-Faria F, Menuchi MRTP, Vitório R, Gobbi LTB, Stella F, et al. (2006) Kinematic parameters of gait with obstacles in elderly patients with Parkinson's disease, with and without levodopa effect: a pilot study. *Braz J Phys Ther* 10: 233-239.
6. Guyton AC; Hall JE (2011) *Treaty of Medical Physiology*. In: Dual pathways for the transmission of pain signals to the central nervous system and base ganglia-Their motor functions. (12th edn), Elsevier, pp: 618-20, 728-32.
7. O'Sullivan SD (2004) Parkinson's disease. In: O'Sullivan SD, Schmtz TJ. *Physiotherapy- evaluation and treatment*. (4th edn), São Paulo: Manole pp: 747-782.
8. Holden A, Wilman A, Wieler M, Martin WRW (2006) Basal ganglia activation in Parkinson's disease. *Parkinsonism Relat Disord* 12: 73-77.
9. Pereira JAC, Gaiad TP, Santos AP (2016) Effect of task-oriented circuit training on motor performance and quality of life of patients with Parkinson's disease: A case study. *J Occup Ther* 27: 329-335.
10. Lemke MR, Brecht HM, Koester J, Kraus PH, Reichmann H (2005) Anhedonia, depression, and motor functioning in Parkinson's disease during treatment with pramipexole. *J Neuropsychiatry Clin Neurosci* 17: 214-220.
11. Santos-Garcia D, Aneiros-Díaz A, Macías-Arribi M, Llaneza-González MA, Abella-Corral J, et al. (2010) Sensory symptoms in Parkinson's disease. *Rev Neurol* 50: 65-74.
12. Simons DG, Travell JG, Simons LS (1999) *Myofascial pain and dysfunction, the trigger point manual*. William & Wilkins, Baltimore, USA.
13. Nascimento ICB, Oliveira dos Santos RDC, Guerreiro CF, Nóbrega da Costa AC, Camelier FWR (2016) Postural evaluation in people with Parkinson's disease: A state of art. *RPF* 6: 56-64.
14. Goetz CG, Tanner CM, Levy M, Wilson RS, Garron DC (1986) Pain in Parkinson's disease. *Mov Disord* 1: 45-49.
15. Karu TI (1988) Molecular mechanism of the therapeutic effect of low-intensity laser irradiation. *Dokl Akad Nauk SSSR* 291: 1245-1249.
16. Cunha AA (2001) *Ventosaoterapia: Treatment and practice*.
17. Hoehn MM, Yahr MD (1967) Parkinsonism: Onset, progression and mortality. *Neurology* 17: 427-442.