

Review Article

Ocular Toxoplasmosis: Controversies in Primary and Secondary Prevention

Norman A. Saffra,^{1,2} Carly J. Seidman,^{1,2} and Louis M. Weiss³

¹Division of Ophthalmology, Maimonides Medical Center, Brooklyn, NY 11219, USA

²Department of Ophthalmology, New York University, New York, NY 10016, USA

³Departments of Medicine and Pathology, Albert Einstein College of Medicine, Yeshiva University, Bronx, NY 10461, USA

Address correspondence to Norman A. Saffra, eyesitemd@gmail.com

Received 6 January 2013; Accepted 23 February 2013

Copyright © 2013 Norman A. Saffra et al. This is an open access article distributed under the terms of the Creative Commons Attribution License, which permits unrestricted use, distribution, and reproduction in any medium, provided the original work is properly cited.

Abstract Ocular toxoplasmosis is the most common cause of posterior uveitis in the United States and worldwide. It commonly follows a relapsing course with the potential for multiple adverse visual sequelae and, rarely, blindness. Both immune-competent and immune-suppressed populations can develop severe relapsing disease. There is considerable debate regarding the initial treatment of ocular toxoplasmosis in both groups, with multiple antiparasitic agents commonly used with little evidence to support any particular regimen. The precise role of corticosteroids in treatment also has yet to be rigorously defined. Secondary prevention is commonly implemented in the immune suppressed population, but there is a lack of level one evidence to support its role in immune-competent patients, though it warrants future investigation.

Keywords antiparasitic therapy; chemoprophylaxis; infectious retinal disease; ocular toxoplasmosis; retinochoroiditis; secondary prevention

1. Epidemiology

Toxoplasma gondii is the most common agent causing retinal infection in the United States, with over one million individuals infected with the intracellular parasite. Of this number, over 21,000 individuals develop ocular toxoplasmosis, and nearly 5,000 manifest visual symptoms [9]. Surprisingly, given its ubiquity, the treatment of ocular toxoplasmosis is the subject of much controversy even among uveitis experts [2,8,21].

2. Pathophysiology

Ocular toxoplasmosis can take on a prolonged and relapsing course in humans. *T. gondii* exists in three forms: oocyst (sexual life cycle stage), tachyzoite (rapidly replicating form), and bradyzoite (latent tissue cyst life cycle stage) (Figure 1). Cats are the definitive host—the parasite reproduces in feline intestines and is shed in the feces in large numbers. Transmission occurs when oocysts (which contain sporozoites) or tissue cysts (which contain bradyzoites) are ingested (Figure 2).

In humans, this parasite can be acquired *in utero* or postnatally from environmental exposure. This can be through contact with cat feces or litter or ingestion from a variety of routes, including infected water, produce, or undercooked meat (pregnant seronegative women should therefore avoid these exposures). It can also be acquired via blood transfusion or organ transplantation. *T. gondii* tachyzoites can invade any host cells in the body, including those of the retina and choroid, where it transforms to bradyzoites (tissue cysts) and becomes dormant, but can reactivate and cause infection at any time. Toxoplasma retinochoroiditis may be the result of the immune system reaction to parasite antigens [15].

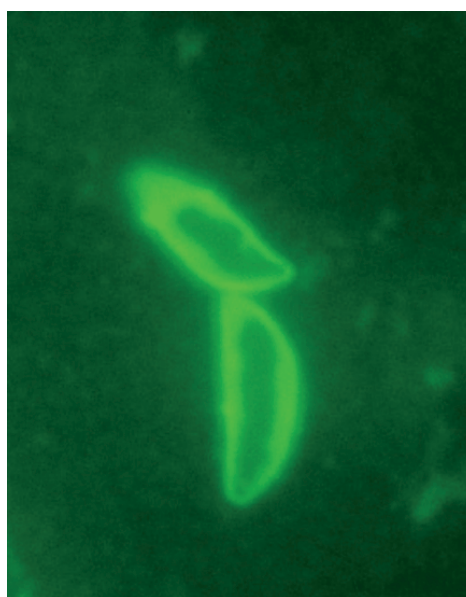


Figure 1: SAG1 antibody-stained *T. gondii* tachyzoites.

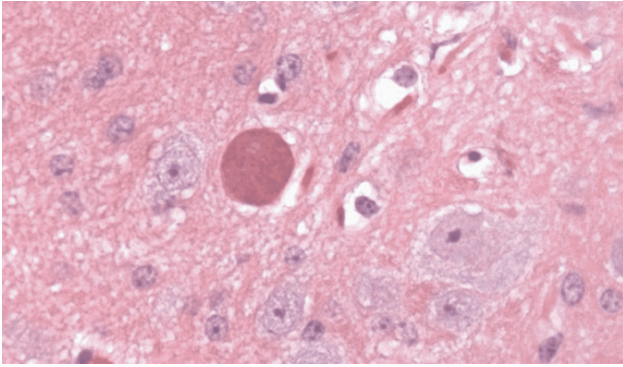


Figure 2: H&E stain demonstrating *T. gondii* cyst in brain tissue.

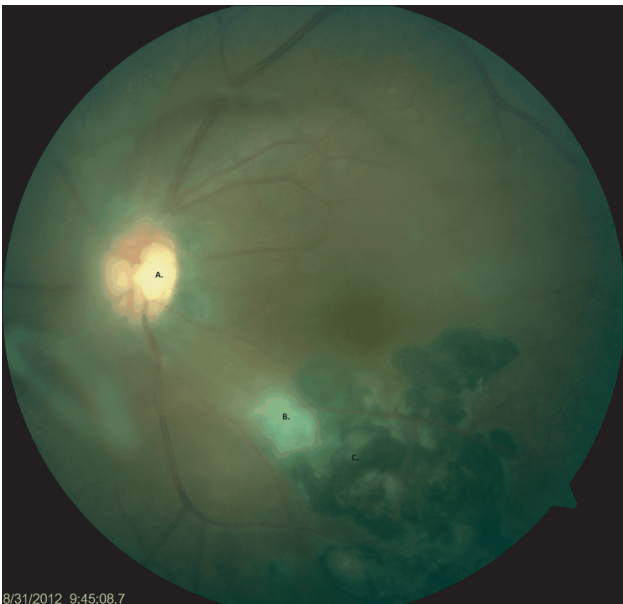

Figure 3: Color fundus photo from a 34-year-old immunocompetent female with multiple recurrences in the posterior pole. A. Weiss ring. B. Area of vitritis overlying active lesion. C. Chronic scarring from prior episodes.

3. Signs and symptoms

The ophthalmic presentation of ocular toxoplasmosis typically depends on the retinal location of the lesion (central or peripheral retina) and the associated degree of inflammation (Figures 3, 4, and 5). Patients classically present with a unilateral decrease in vision with associated floaters. Pain, redness, and photophobia (symptoms of acute anterior uveitis) can be present as well.

The classic presentation of congenital toxoplasmosis includes large macular retinochoroiditis, hydrocephalus, and intracranial calcification. Recurrent disease is marked by the presence of active lesions in the setting of old pigmented retinal scars in either eye.

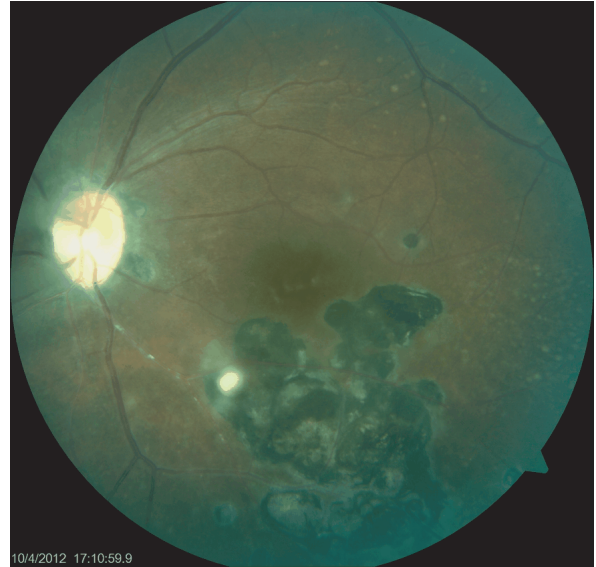


Figure 4: Color fundus photo of same patient midway through therapy with Bactrim and prednisone, showing decrease in size of active lesion and resolution of vitritis.

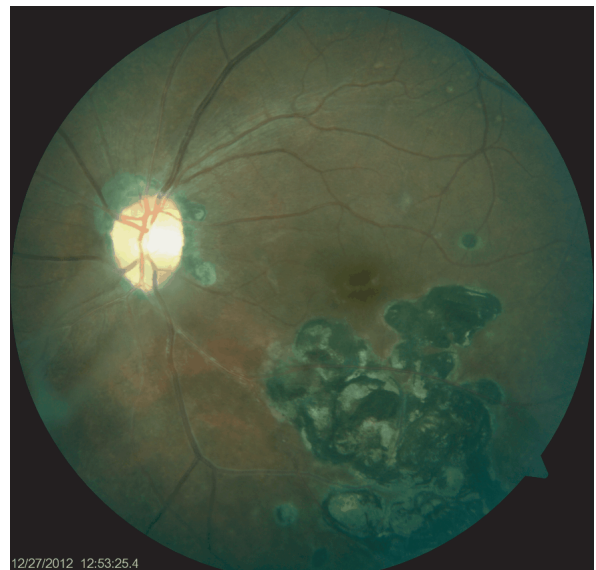

Figure 5: Color fundus photo following eight weeks of therapy with Bactrim DS and prednisone, demonstrating resolution of the active lesion, clearing of vitritis, and increased scarring in the posterior pole.

4. Diagnosis

The diagnosis of toxoplasmosis infection is usually made by physical examination, via a dilated funduscopic examination with the use of serology as a confirmation. The retinitis is most often located in the posterior pole and occasionally adjacent to or involving the optic nerve. Serologic testing via ELISA and indirect fluorescent antibody testing is

commonly used to confirm the diagnosis of ocular toxoplasmosis. The presence of IgG antibodies to *T. gondii* (which appear two weeks after exposure) confirms past exposure and titers remain detectable for life. The presence of IgM or IgA antibodies signal the acute phase and remain elevated for approximately one year after exposure. The presence of IgM antibodies, therefore, likely confirms the presence of active disease [7]. PCR amplification of *T. gondii* DNA is more sensitive and specific and can also be used as confirmatory. However, serologic testing is not prognostic as there is no correlation between antibody titers, DNA load, and severity of ocular disease [4].

5. Disease course

The impact of ocular toxoplasmosis is far ranging with the potential for cataract, glaucoma, vitreous opacification or hemorrhage, macular scarring, macular cystoid edema, choroidal neovascular membrane, retinal detachment, vascular occlusion, and optic nerve involvement [15]. Punctate outer retinal toxoplasmosis (PORT), characterized by small, deep multifocal lesions with overlying vitreous inflammation, can also occur. The development of these various sequelae often depends upon the patient's immune status and age. The immune compromised and elderly are at higher risk for severe adverse outcomes and bilateral involvement over time [5]. Although infection in the immune-competent host most commonly results in an acute, self-limited chorioretinitis (lasting 6 to 8 weeks), with the likely formation of a retinal scar, these patients are still at risk for recurrence of infection, causing additive damage each time. The factors that predispose certain individuals to recurrent infection are likely multifactorial and may be related to the strain of parasite and age of the patient, but there are no studies to support this.

Treatment of ocular toxoplasmosis is controversial, as multiple regimens are used, and there is little evidence in support of their relative efficacy and in which populations to implement them [6]. Whereas secondary prevention is commonly implemented in immune-compromised patients, there is debate as to whether immune-competent patients should be candidates for long-term prophylaxis against recurrence [8,21].

6. Therapy

The goal of treating toxoplasmosis is to limit the duration of active parasitic infection so that cicatrization can occur more quickly, and the extent of structural complications is limited. It is known that a combination of glucocorticoids and antibiotics treating immune-competent patients, in whom the infection is self-limited, is likely effective in altering the short-term natural course of the disease. More evidence is needed to evaluate longer therapies. In considering whether to treat, the benefits of treatment must be weighed against the potential risks associated with antibiotic

therapy. Such adverse effects range from gastrointestinal distress to rash, thrombocytopenia, leucopenia, and drug allergy/anaphylaxis. Due to these rare but possible side effects, some experts opt against treating low-risk cases in immune-competent patients who exhibit only small peripheral lesions [2,21]. However, it is agreed that the immune-suppressed state, pregnancy, and congenital toxoplasmosis (diagnosed within the first year of life) are absolute indications for therapy [2,21].

In choosing a therapeutic regimen, multiple choices are available, although no evidence-based standards are available. Among members of the American Uveitis Society, 9 different antiparasitic agents were used in 24 different combinations [8]. There have only been three randomized placebo-controlled trials investigating the efficacy of different antibiotic therapies, and these are methodologically weak and outdated [6]. Most therapeutic regimens are, thus, chosen based upon a limited number of case studies and individual ophthalmologists' preferences.

Classic therapy, "triple therapy," is the most commonly implemented regimen and includes pyrimethamine (loading dose of 50 to 100 mg then 25 to 50 mg QD), sulfadiazine (2 to 4 g loading dose then 1 g QID), and oral corticosteroids (0.5 to 1.0 mg/kg QD). Sulfadiazine is known to cause a rare but severe systemic anaphylactic reaction. Pyrimethamine is known to cause pancytopenia and requires weekly monitoring of blood counts; folinic acid is usually coadministered with the drug to prevent bone marrow suppression. "Quadruple therapy" also includes clindamycin (300 mg QID) [8]. Bactrim (trimethoprim-sulfamethoxazole) (160 mg/80 mg BID) has been successfully substituted in place of pyrimethamine and sulfadiazine [19]. Other newer agents, including macrolides, tetracyclines, atovaquone, and antiparasitic agents, have also been used when there is intolerance to classic therapy [1,16].

Duration of therapy typically spans from four to six weeks or in the immunosuppressed—as long as one year [2,21]. Newborns are usually treated with pyrimethamine and sulfonamides for one year. Local therapy utilizing intravitreal injections of clindamycin is an emerging regimen that can be potentially used as an adjunct to local therapy or as an option for patients with contraindications to systemic therapy (or pregnant women to reduce teratogenicity). It is known to achieve good intracellular concentration in the intraocular tissues, thus targeting the parasite [18] is less expensive than most antiparasitic agents, and compliance is less of an issue than with oral regimens. The recommended dose ranges from 1.0 mg/0.1 mL to 1.5 mg/0.1 mL and is administered between one to four times (given 2 weeks apart), or until complete clinical improvement is achieved [21].

In one study, intravitreal clindamycin in conjunction with local dexamethasone injections were shown to be

effective in controlling toxoplasma retinochoroiditis and improving visual acuity at 11 to 26 months follow-up; on average, two to four injections were required [11]. Another clinical trial compared intravitreal clindamycin with local dexamethasone injections to classic therapy and found them comparable in terms of reduction of lesion size, decreased vitritis, and improvement in visual acuity. Classic therapy was noted to be more effective in IgM positive patients, however, suggesting that intravitreal therapy might be less appropriate in patients with reactivation toxoplasmosis [18]. As the sample sizes were small, however, more adequately powered studies are needed to assess the efficacy of intravitreal therapy.

Regimens are often altered in the setting of pregnancy so as to avoid teratogenic effects. Some experts avoid systemic therapy and recommend intravitreal clindamycin instead [13,18,21]. If systemic therapy is to be used, spiramycin is considered the preferred agent in the first trimester, although it does not cross the placenta or treat the fetus. Classic triple therapy is considered to be acceptable beginning in the second trimester, however, and some advocate earlier use of these agents.

Corticosteroids (topical, oral, and intravitreal) also commonly play a role in the treatment of ocular toxoplasmosis, but as with antimicrobial therapy, there are no evidence based standards to quantify or support their use. They are thought to reduce intraocular inflammation, but do not treat the infectious component of the disease [21]. Monotherapy with corticosteroids is, therefore, not recommended. Without concomitant antibiotic use, steroids can actually cause tissue destruction, especially in immune compromised patients. Moreover, corticosteroid monotherapy does not prevent disease recurrence [3]. Many experts recommend adding corticosteroids to antiparasitic therapy in the presence of vitritis, macular edema, lesions close to the fovea, optic neuritis, and in monocular patients [21]. Most experts also agree on prescribing topical corticosteroids in the presence of anterior uveitis [21]. Concerning the time frame relative to antiparasitic therapy, some experts initiate corticosteroids simultaneously, whereas others wait anywhere from 1 day up until 1 week. There is a lack of consensus as to duration of corticosteroid therapy [8].

Of note, surgical options are also occasionally implemented in the treatment of ocular toxoplasmosis. These include photocoagulation, cryotherapy, and vitrectomy; but their efficacy has not been proven. Use of such modalities on an actively inflamed retinal can be dangerous [15].

7. Secondary prevention

It has been acknowledged that the short-term treatment of ocular toxoplasmosis does not prevent the long-term recurrence of disease. Recurrence of ocular toxoplasmosis is common; in treated patients, rates have ranged from

40% [20] to 79%, although studies have been limited by follow-up [20]. Therefore, there is a question as to whether to initiate chemoprophylaxis in certain patients as secondary prevention; the long-term impact on relapse, scarring, and visual acuity has not been studied.

In *T. gondii*-seropositive immune-suppressed patients with signs of ocular disease, chemoprophylaxis is common practice and may reduce disease occurrence [10]. There are no evidence-based recommendations regarding therapy, but some recommendations state that following resolution of active disease that the original treatment be continued at one half of the initial dose for the lifetime of the patient or until the immune-suppressive condition has ceased. In patients with HIV, prophylaxis should be continued until the CD4 count rises above 200 [14].

Less clear is whether immune-competent patients should receive chemoprophylaxis. It has been recommended in patients with more severe disease, history of more frequent recurrences (i.e., greater than one per year or three in two years) and those at high risk of vision loss (i.e., those with significant scarring in the posterior pole or adjacent to the fovea). Postoperative prophylaxis has also been recommended in patients with a history of toxoplasmosis following cataract extraction or vitrectomy [13]. Some experts actually recommend a course of chemoprophylaxis in all patients treated for active disease, as it has been hypothesized that recurrence risk is greatest early on but decreases over time [17].

A commonly described regimen consists of macrolide therapy to avoid eliciting an allergy to sulfonamides during chemoprophylaxis. Silveira used one tablet of trimethoprim-sulfamethoxazole (TMP-SMX) (160/800) every three days, although other regimens have also been used this is often chosen for its convenience, cost effectiveness, and low rate of side effects. Silveira et al. [17] found that this regimen was associated with significantly fewer recurrences of disease, and other case studies also report success with TMP-SMX [12], but studies have been limited by study bias, sample size, and duration of follow-up. It should be noted that TMP-SMX is not as effective as pyrimethamine and sulfadiazine in the treatment of acute disease; therefore, although it has fewer side effects, it might not offer the best protection against recurrence over time. More information on TMP-SMX as well as other prophylactic regimens is needed.

8. Conclusions

Despite the ubiquity of ocular toxoplasmosis, there remains a lack of standardized evidence regarding its treatment and prevention. However, in general, the trend does appear to be more aggressive treatment, even of milder disease [8]. There is a need for well-controlled trials to determine the relative efficacy of initial therapies as well as to explore chemoprophylactic regimens and their sight-saving impact.

Acknowledgments The authors report no conflicts of interest. The authors alone are responsible for the content and writing of the paper. Louis M. Weiss is supported by NIH-NIAID grant AI094094-02.

References

- [1] K. Balaskas, J. Vaudaux, N. Boillat-Blanco, and G.-C. Y., *Azithromycin versus sulfadiazine and pyrimethamine for non-vision-threatening toxoplasmic retinochoroiditis: a pilot study*, *Med Sci Monit*, 18 (2012), 296–302.
- [2] A. A. Bonfioli and F. Orefice, *Toxoplasmosis*, *Semin Ophthalmol*, 20 (2005), 129–141.
- [3] L. E. Bosch-Driessen, T. T. Berendschot, J. V. Ongkosuwito, and A. Rothova, *Ocular toxoplasmosis: clinical features and prognosis of 154 patients*, *Ophthalmology*, 109 (2002), 869–878.
- [4] G. Bou, M. S. Figueroa, P. Martí-Belda, E. Navas, and A. Guerrero, *Value of PCR for detection of Toxoplasma gondii in aqueous humor and blood samples from immunocompetent patients with ocular toxoplasmosis*, *J Clin Microbiol*, 37 (1999), 3465–3468.
- [5] A. G. Commodaro, R. N. Belfort, L. V. Rizzo, C. Muccioli, C. Silveira, M. N. Burnier Jr., et al., *Ocular toxoplasmosis: an update and review of the literature*, *Mem Inst Oswaldo Cruz*, 104 (2009), 345–350.
- [6] R. E. Gilbert, S. E. See, L. V. Jones, and M. S. Stanford, *Antibiotics versus control for toxoplasma retinochoroiditis*, *Cochrane Database Syst Rev*, (2002), CD002218.
- [7] G. N. Holland, *Ocular toxoplasmosis: a global reassessment. Part II: disease manifestations and management*, *Am J Ophthalmol*, 137 (2004), 1–17.
- [8] G. N. Holland and K. G. Lewis, *An update on current practices in the management of ocular toxoplasmosis*, *Am J Ophthalmol*, 134 (2002), 102–114.
- [9] J. L. Jones and G. N. Holland, *Annual burden of ocular toxoplasmosis in the United States*, *Am J Trop Med Hyg*, 82 (2010), 464–465.
- [10] S. J. Kim, I. U. Scott, G. C. Brown, M. M. Brown, A. C. Ho, M. S. Ip, et al., *Interventions for toxoplasma retinochoroiditis: a report by the American Academy of Ophthalmology*, *Ophthalmology*, 120 (2013), 371–378.
- [11] K. Kishore, M. D. Conway, and G. A. Peyman, *Intravitreal clindamycin and dexamethasone for toxoplasmic retinochoroiditis*, *Ophthalmic Surg Lasers*, 32 (2001), 183–192.
- [12] R. Kopec, G. De Caro, E. Chapnick, M. Ghitan, and N. Saffra, *Prophylaxis for ocular toxoplasmosis*, *Clin Infect Dis*, 37 (2003), e147–e148.
- [13] C. Martinez, D. Zhang, M. Conway, and G. Peyman, *Successful management of ocular toxoplasmosis during pregnancy using combined intraocular clindamycin and dexamethasone with systemic sulfadiazine*, *Int Ophthalmol*, 22 (1998), 85–88.
- [14] J. G. Montoya and L. O., *Toxoplasmosis*, *Lancet*, 363 (2004), 1965–1976.
- [15] S. Pineles, S. M. Ridders, and R. D. Levinson, *Ocular toxoplasmosis*, in *Ophthalmology*, M. Yanoff and J. S. Duker, eds., Mosby, Maryland Heights, MO, 3rd ed., 2009.
- [16] A. Rothova, L. Bosch-Driessen, N. van Loon, and W. Treffers, *Azithromycin for ocular toxoplasmosis*, *Br J Ophthalmol*, 82 (1998), 1306–1308.
- [17] C. Silveira, R. Belfort Jr., C. Muccioli, G. N. Holland, C. G. Victora, B. L. Horta, et al., *The effect of long-term intermittent trimethoprim/sulfamethoxazole treatment on recurrences of toxoplasmic retinochoroiditis*, *Am J Ophthalmol*, 134 (2002), 41–46.
- [18] M. Soheilian, A. Ramezani, A. Azimzadeh, M. M. Sadoughi, M. H. Dehghan, R. Shahghadami, et al., *Randomized trial of intravitreal clindamycin and dexamethasone versus pyrimethamine, sulfadiazine, and prednisolone in treatment of ocular toxoplasmosis*, *Ophthalmology*, 118 (2011), 134–141.
- [19] M. Soheilian, M. M. Sadoughi, M. Ghajarnia, M. H. Dehghan, S. Yazdani, H. Behboudi, et al., *Prospective randomized trial of trimethoprim-sulfamethoxazole versus pyrimethamine and sulfadiazine in the treatment of ocular toxoplasmosis*, *Ophthalmology*, 112 (2005), 1876–1882.
- [20] J. C. Timsit and E. Bloch-Michel, *Efficacy of specific chemotherapy in the prevention of recurrences of toxoplasmic chorioretinitis during the 4 years following treatment*, *J Fr Ophthalmol*, 10 (1987), 15–23.
- [21] D. Wakefield, E. T. Cunningham Jr., C. Pavesio, J. G. Garweg, and M. Zierhut, *Controversies in ocular toxoplasmosis*, *Ocul Immunol Inflamm*, 19 (2011), 2–9.