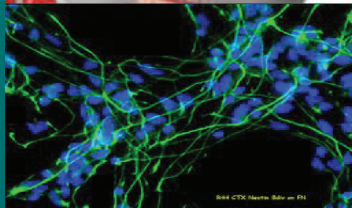
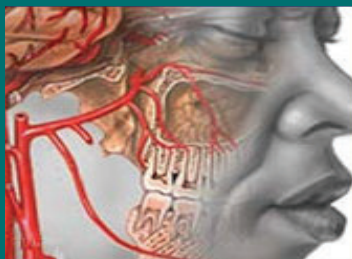

The Journal of Neuroinfectious Diseases (formerly Journal of Neuroparasitology) is a scholarly open access, peer-reviewed, and fully refereed journal dedicated to developing a home for the reporting of biomedical studies that bridge the fields of infectious diseases and neuroscience. Neurological sequelae of infectious diseases are of critical importance. Infections such as those caused by eukaryotes including protozoa, helminths, and fungi as well as viral and bacterial infections will be considered for publication in this journal.

The journal provides scientists and clinicians with a unique format for peer-reviewed publication of basic science research findings, clinical studies, case reports, focused and comprehensive reviews, and topical commentaries and perspectives through a very genuine editorial tracking system. JNID is also presented with a vision of providing the young talents a platform to encourage them to develop and globalize their skills and talents for the welfare of the society they are associated with and ultimately to the whole world.



Journal of Neuroinfectious Diseases

Open Access

Editors & Editorial Board


<http://www.omicsonline.com/open-access/neuroinfectious-diseases.php>



Herbert B. Tanowitz
Aligarh Muslim University
India



David C. Spray
Albert Einstein College
of Medicine, USA



F. S. Machado
Federal University of
Minas Gerais
Brazil



C. Albanese
Georgetown University
Medical Center, USA



Christina M. Coyle
Albert Einstein College of
Medicine, USA



M. S. Desruisseaux
Albert Einstein College of
Medicine
USA



Eugene J. Fine
Albert Einstein College
of Medicine
USA



Nisha Jain Garg
University of Texas
Medical Branch
USA



Robert Gilman
Johns Hopkins University
USA




Linnie M. Golightly
Weill-Cornell Medical
College, USA



Georges E. R. Grau
Sydney Medical School
University of Sydney
Australia



F. Marciano-Cabral
Commonwealth
University, USA



Louis M. Weiss
Albert Einstein College of
Medicine, USA



A. Clinton White, Jr
University of Texas
Medical Branch
USA



J. Lannes-Vieira
Oswaldo Cruz
Institute- Fiocruz
Switzerland



Peter Kennedy
Southern General
Hospital Glasgow,
Scotland, UK



Sandra K. Halonen
Montana State University
USA



Danny A. Milner, Jr
Harvard Medical
School, University of
Malawi, USA



Hector H. Garcia
Universidad Peruana
Cayetano Heredia
Peru



G. S. Visvesvara
Centers for Disease Control
and Prevention
Chamblee, GA, USA



Rolf Dermietzel
Ruhr-Universität
Bochum
Germany



Renato Rozental
Medical College of
Georgia, Brazil



Norman Saffra
Maimonides Medical
Center, USA



Joseph Ndung'u
Foundation for
Innovative New
Diagnostics Geneva
Switzerland

Journal of Neuroinfectious Diseases-Open Access using online manuscript submission, review and tracking systems of Editorial Manager® for quality and quick review processing. Submit your manuscript at <http://www.omicsgroup.info/editorialtracking/neurodiseases/SubmitManuscript.php>

OMICS Publishing Group

5716 Corsa Ave., Suite 110, Westlake, Los Angeles, CA 91362-7354, USA, Phone: +1-650-268-9744, Fax: +1-650-618-1414, Toll free: +1-800-216-6499

Research Article

Prevalence and Morphological Characteristics of *Taenia multiceps* Cysts (Coenurus Cerebralis) from Abattoir-Slaughtered and Experimentally Infected Goats

Sonia M. S. Afonso,¹ Samson Mukaratirwa,² Katarina Hajovska,¹ Bettencourt P. S. Capece,¹ Carles Cristòfol,³ Margarita Arboix,³ and Luís Neves¹

¹Faculty of Veterinary Science, Eduardo Mondlane University, Av. de Moçambique, km 1.5, P.O. Box 257, Maputo, Mozambique

²School of Biological and Conservation Sciences, University of KwaZulu-Natal, Biological Science Building, Westville Campus, Durban 4000, South Africa

³Department of Pharmacology, Therapeutics and Toxicology, Autonomous University of Barcelona, 08193 Bellaterra, Barcelona, Spain

Address correspondence to Sonia M. S. Afonso, safonso9@hotmail.com

Received 5 December 2011; Revised 21 December 2011; Accepted 23 December 2011

Abstract One hundred and forty nine indigenous goats slaughtered at the Tete municipal abattoir, Mozambique, and fifty seven goats experimentally infected with *Taenia multiceps* eggs were inspected to determine the prevalence, predilection sites and morphological characteristic of cysts and scoleces of *T. multiceps*. The experimentally infected goats of mixed sexes were divided into Group one (28 animals slaughtered at 10 weeks post-infection) and Group two (29 animals slaughtered at 22 weeks post-infection). Each animal was experimentally infected with 3000 eggs of *T. multiceps* recuperated from experimentally infected dogs. The prevalence of infection was 14.8% in the naturally infected goats, 78.6% for Group 1 and 82.8% for Group 2 of the experimentally infected goats. The muscle and subcutaneous tissues were the most common anatomic location of cysts in both the naturally and experimentally infected (Group 1 and 2) goats with a prevalence of 9.1%, 82% and 75% respectively and this was followed by the brain in the naturally infected (8.5%), and Group 2 (11.4%) and the heart and mesentery (4.5%) in Group 2. In the abattoir-slaughtered goats, animals with one cyst were more frequent in both muscular and subcutaneous tissues (73.3%) and brain (75%) and fewer animals were found to harbor two or more cysts.

Keywords *Taenia multiceps*; coenurus cerebralis; cysts; meat inspection; goats; Mozambique; predilections sites

1 Introduction

Taenia multiceps (Leske, 1780) (syn. *Multiceps multiceps*) is a worldwide parasite which inhabits the small intestine of dogs, foxes, coyotes and jackals [22]. The larval stage, known as coenurus cerebralis, causes a central nervous system disease in sheep commonly known as coenurosis,

gid or sturdy and may also affect other animal species such as domestic and wild ruminants including humans [5, 14, 23, 26, 29, 30]. Apart from the cerebral form, which is usually fatal, intramuscular and subcutaneous connective tissues, liver, lung forms have been reported to occur [26].

Animal cerebral coenurosis is usually diagnosed based on a clinical examination protocol [16, 24, 25] and seldom includes imaging methods like radiology [28], ultrasonography [8] and computed tomography [12] which are mainly used in experimental situations. Immunodiagnosis tests such as skin test for immediate hypersensitivity, indirect haemagglutination antibody (IHA) test, immuno-electrophoresis (IEP), gel double diffusion (DD), immunoblot and enzyme linked immune-assay (ELISA) tests have been used experimentally [6, 7, 21, 25]. Despite the availability of these tests which have their own practical challenges, post mortem findings of a thin walled cyst filled with transparent fluid and with numerous scoleces in the wall remain the definitive diagnosis [15, 26].

The prevalence of *T. multiceps* larva in Gaza and Tete Provinces of Mozambique has been reported to range from 7.3% to 13.8% based on abattoir findings [3, 32]. To the best of our knowledge, no other data exist on the occurrence of coenurosis in Mozambique and no references have been made to the site of predilection and the morphological characteristics of the larva and scoleces in goats. For this reason, the present study was conducted to determine the prevalence and predilection sites of *T. multiceps* cysts in goats slaughtered at a local abattoir and those experimentally infected and the morphological characteristics of the cysts and scoleces. The results will add new information on the predilection sites of *T. multiceps* in goats and assist meat inspectors in locating the cysts at abattoirs during meat inspection.

Groups	N	Infective dose/animal	Week of slaughter post-infection
1. Experimentally infected	28	3000	10
2. Experimentally infected	29	3000	22
3. Abattoir-slaughtered	149*	Not known	Not known

*Refer to organs and not number of goats.

Table 1: Experimental design of the study.

2 Material and methods

2.1 Meat inspection at abattoir

Various organs and muscle tissues from a total of 169 abattoir-slaughtered goats of local breeds of mixed sexes from a municipal abattoir in Tete Province, central west region of Mozambique, were inspected for the presence of *T. multiceps* cysts [22]. The number of organs and muscle tissues accessed for inspection varied as it depended on willingness of owners to access them for thorough inspection.

2.2 Experimental animals

2.2.1 Goats

The experimental study was conducted at the Veterinary Faculty, Eduardo Mondlane University (EMU), Mozambique. Fifty seven male goats of local breed, *Landin*, aged between 8 and 18 months old were purchased from *T. multiceps*-free farms. In order to assess the morphological characteristics of *T. multiceps* cysts at different weeks post-infection, the animals were randomly divided into two groups (Group one, 28 animals and Group two, 29 animals) (Table 1). Animals were housed at the Veterinary Faculty, EMU campus, under good clinical practice with free access to food (hay and grain ration) and water. The adaptation period, from purchase to infection, was four months. The study was approved by the Scientific Committee from the Veterinary Faculty, EMU.

2.2.2 Dogs

Six puppies of mixed breed (3 for each experiment) from the same breed and litter were selected for experimental infection with *T. multiceps* scoleces to generate eggs for experimental infection of goats. The puppies were weaned at 2 months and kept in separate kennels at the EMU veterinary hospital. They were fed commercial dog food, supplied with clean water *ad libitum* and treated following prophylactics measures established at the EMU veterinary hospital as follows: multiple vaccination against the common viral diseases including rabies and deworming with a combination of pyrantel, oxfantel and praziquantel (Canex-4®) one month before the experimental infection. The health of the dogs was routinely monitored throughout the period of the study.

2.3 Experimental infection in dogs

Taenia multiceps cysts collected from naturally-infected goats from Tete municipal abattoir were immediately

processed after collection by removing tissue surrounding the cysts. This was followed by washing the cysts in phosphate buffer saline (PBS), pH 7.3, preserving them in a sterile recipient and maintaining them at 4 °C until time of infection.

The dogs were each orally infected with 100 scoleces at the age of four months. Patency was evaluated by collecting faecal samples from infected dogs once a week to detect taeniidae eggs using the McMaster flotation technique [15]. After the parasite had reached patency, shown by presence of taenid eggs in faeces, the dogs were euthanized with 20% pentobarbital (Eutha-Naze) at a dose of 200 mg/kg. *Taenia multiceps* adult parasites were removed from the small intestine and gravid proglottids were separated to recover the eggs.

Standard operating procedures regarding the safety of researchers were strictly followed at all stages of the experimental infection. The dog kennels were kept isolated and access was restricted to the researchers only. All faeces from the infected dogs were incinerated as from day one post-infection.

2.4 Experimental infection in goats

Gravid proglottids of *T. multiceps* were crushed in 2.5% potassium dichromate to release the eggs and the eggs were preserved in a refrigerator at 4 °C before being subjected to the hatching process. In vitro hatching was performed using sodium hypochlorite [17,27,33]. Briefly, eggs were centrifuged at 1000 rpm for 5 minutes and 0.5 mL of sodium hypochlorite (0.5% of sodium hypochlorite in normal saline) and 10 mL of formol saline were added. The solution was centrifuged at 1000 rpm for 5 minutes. The sediment, containing the hatching eggs, was washed three times in normal saline and counted [17,27,33]. Each goat was orally infected with 3000 viable eggs via a cellulose and amide bolus.

Group one animals were slaughtered at 10 weeks post-infection and Group two at 22 weeks post-infection. The procedure for localization of cysts from the various organs and tissues was done following the anatomic classification according to following authors [19,20]. Cysts were removed from the tissue and then washed with phosphate saline buffer (PBS) pH 7.3 and placed in a Petri dish. The number of scoleces from each cyst was determined and the length and width of the scoleces were measured with a ruler under a stereomicroscope.

Location	Prevalence of cysts (%)		
	Abattoir-slaughtered <i>N</i> (% infected)	Experiment 1 <i>N</i> (% infected)	Experiment 2 <i>N</i> (% infected)
Muscle and subcutaneous tissue*	149 (9.1)	28 (82.0)	29 (75.0)
Brain	142 (8.5)	28 (5.0)	29 (11.4)
Mesentery	115 (1.7)	28 (0.0)	29 (4.5)
Lungs	149 (0)	28 (1.0)	29 (2.3)
Diaphragm	115 (0)	28 (5.0)	29 (2.3)
Heart	149 (0)	28 (7.0)	29 (4.5)
Overall prevalence	169 (14.8)	22 (78.6)	24 (82.8)

N = sample size; Experiment 1 = 10 weeks post-infection; experiment 2 = 22 weeks post-infection; *Muscle and subcutaneous tissue include muscles from the neck region, thoracic region, abdominal wall, lumbar and pelvic region.

Table 2: Prevalence of *Taenia multiceps* cysts (*coenurus cerebralis*) at various locations in abattoir-slaughtered and experimentally infected goats.

2.5 Data analysis

Descriptive statistics which included the determination of prevalence of *T. multiceps* cysts in abattoir-slaughtered and the experimentally infected goats were calculated. Data on the location of cysts from the abattoir-slaughtered and the experimentally infected goats were compared using a chi-square test with the level of significance set at $P < .05$. The computer software SPSS 13.0 SPSS Inc., Chigago, IL, was used for data analysis.

3 Results

The overall prevalence of *T. multiceps* cysts in abattoir-slaughtered goats determined through meat inspection was 14.8% (22/149) and of experimentally infected goats was 78.6% (22/28) and 82.8% (24/29) for group one and two respectively (Table 2). The muscle and subcutaneous tissues were the most common anatomic location of cysts in both the naturally and experimentally (Group one and two) infected goats with a prevalence of 9.1%, 82% and 75% respectively and this was followed by the brain in the abattoir-slaughtered group (8.5%), and Group two (11.4%) and the heart (7.0%) and diaphragm (5.0%) in Group one animals. A low number of cysts was observed in the brain (5% for Group one and 11% for Group two). Overall, *T. multiceps* cysts were distributed to a minimum of five anatomical sites in the experimentally infected goats whilst they were only observed at three sites in the naturally infected goats. It is worth mentioning that muscle and subcutaneous tissue included muscles from the neck, thoracic, lumbar and pelvic region and abdominal wall. A significant difference ($P < .05$) was observed between the number of cysts observed in the brain of abattoir-slaughtered goats and experimentally infected animals with the abattoir-slaughtered animals having more cysts in the brain. There was no significant difference ($P > .05$) in the number of cysts observed in the muscles and subcutaneous tissue between the two groups.

The morphological characteristics of the *T. multiceps* cysts from naturally and experimentally infected goats were similar. Cysts were composed of a hyaline membrane with many scoleces on the inner surface and filled with a translucent fluid of varying volume. In both cases, cysts which were located outside of the brain were surrounded by a thick host membrane.

In the naturally infected group, animals with one cyst were more frequent in both muscular and subcutaneous tissues (73.3%) and brain (75%) and few animals were found to harbor two or more cysts. In the experimentally infected groups, animals with two cysts (11 animals) were the most common and only three goats had 10, 12 and 16 cysts each, respectively.

Size of larvae and number of scoleces per cyst increased with the age as observed at 10 and 22 weeks post-infection (Table 3). Young cysts of 10 weeks of age had fewer scoleces (51.7 ± 27.7) than the older ones of 22 weeks (92.2 ± 48.7).

4 Discussion

In Africa, *T. multiceps* cysts in the central nervous system (CNS) have been reported in domestic ruminants in Kenya, Ethiopia, Democratic Republic of Congo, Senegal, Sudan, Chad, Angola, Southern Africa [30] and Mozambique [32]. However, none of these studies contain information regarding the predilection sites of larval stages. The prevalence of *T. multiceps* cysts in naturally infected goats in this study (14.8%) was higher than the prevalence reported in a retrospective study in sheep in Ethiopia (2.34–4.54%) [2] and in goats in Gaza (8%) and Tete (7.3%) provinces of Mozambique [3] and comparable to the prevalence reported of (13.8%) in a study conducted in Tete abattoir, Mozambique [32]. Prevalence studies of *T. multiceps* infection in small ruminants in Southern African countries are very limited [32] and this study gives an indication that the parasite is wide spread, especially in the

Time of slaughter post-infection	Mean length (range) and width (range) of larva at 10 and 12 weeks post-infection		
	<i>N</i>	Mean length \pm sd (min-max)	Mean width \pm sd (min-max)
10 weeks	66	2.1 \pm 1.06 (0.1–5.8)	1.4 \pm 0.75 (0.1–5.8)
22 weeks	46	3.38 \pm 1.4 (1.0–6.8)	2.44 \pm 1.12 (1.0–6.8)
	Mean number (range) of scoleces per goat at 10 and 12 weeks post-infection		
	<i>N</i>	Scoleces	
10 weeks	83	51.73 \pm 27.7 (6–181)	
22 weeks	36	92.22 \pm 48.71 (18–206)	

Table 3: Size of *Taenia multiceps* cysts (coenurus cerebralis) and number of scoleces per cyst in experimentally infected goats at 10 and 22 weeks post-infection.

resource-poor rural communities and the zoonotic impact of the parasite is yet to be assessed.

The common predilection sites of *T. multiceps* cysts in sheep is the CNS, whilst in goats, apart from the CNS, the muscle and subcutaneous form have been reported [23,26]. Subcutaneous cysts found in an infected goat were classified as *Multiceps gaigeri* [13] and in subsequent studies similar cysts were found in several organs including muscles and subcutaneous tissue and were re-classified as *T. multiceps* [10,18,23].

Results from our study shows that a larger proportion of *T. multiceps* cysts were found outside the CNS and mostly in muscle and subcutaneous tissues in the experimentally infected goats than the naturally infected. This difference is likely to be due to the fact that the cysts in the muscles of the experimentally infected animals were located in the medium and deep layers of muscles which increase the possibility of becoming unnoticed at abattoir inspection. The low sensitivity of abattoir routine meat inspection for *T. multiceps* cysts is an important factor that may contribute in perpetuating the cycle of the parasite.

Previous experimental infections with *T. multiceps* larva were done in sheep using a high dose of 5500 eggs per sheep [4] and 6500 eggs [11]. In the two studies the infection rate was 100% in contrast to lower infection rates recorded in our study. This difference might have been associated to the combination of a relatively low infection dose, egg viability or regurgitation of the infected bolus.

Previous studies show that clinical coenurosis in sheep is common in young animals [1,22]. Age-related resistance to infection with *T. multiceps* in sheep has been suggested [31], however, the mechanism by which this may come about is not apparent and cross immunity within taeniidae cestodes has been discussed by some authors [9]. The increase with age in cyst size and the number of scoleces found in this study are in accordance with a previous study in sheep [34].

Our findings have shown the prevalence of *T. multiceps* cysts in goats is high in Mozambique and this might be the same situation in most countries in Southern Africa where goats are extensively reared. In addition, an important finding from the experimental infection study

was that the predilection sites, apart from the brain include skeletal muscles and subcutaneous tissue, lungs, diaphragm, heart and mesentery and that the current routine abattoir inspection targeting only the brain is not a reliable method in detecting all cases *T. multiceps* infection in goats. Development and validation of a sensitive and specific diagnostic method for *T. multiceps* infection in goats should be investigated in order to improve the surveillance and control of the parasite.

Acknowledgments This work was supported by the Open Fund from Eduardo Mondlane University (UEM), Maputo, Mozambique. The authors would like to thank all staff at the Tete province municipal abattoir and Veterinary Faculty, Eduardo Mondlane University, who were involved in this work.

References

- [1] M. N. Abo-Shehada, E. Jebreen, B. Arab, R. Mukbel, and P. Torgerson, *Prevalence of Taenia multiceps in sheep in northern Jordan*, *Prev Vet Medicine*, 55 (2002), 201–202.
- [2] M. Acheneff, T. Markos, G. Feseha, A. Hibret, and S. Tembely, *Coenurus cerebralis infection in Ethiopian highland sheep: incidence and observations on pathogenesis and clinical signs*, *Trop Anim Health Prod*, 31 (1999), 15–24.
- [3] A. Atanásio, *Helminths, protozoa, heartwater and the effect of gastrointestinal nematodes on productivity of goats of family sector in Mozambique*, PhD thesis, Medical University of Southern Africa, Medunsa, South Africa, 2000.
- [4] G. Biyikoğlu and A. Doğanay, *Effects of praziquantel and albendazole on Coenurus cerebralis in experimentally infected lambs*, *Turk J Vet Anim Sci*, 22 (1998), 43–48.
- [5] R. Bohrmann, *Coenurus in the muscles of a gemsbok (Oryx gazelle)*, *Vet Parasitol*, 36 (1990), 353–356.
- [6] I. S. Daoud and I. V. Herbert, *Isolation of two lipoprotein antigens from the metacestodes of Taenia hydatigena (Pallas, 1766) and Taenia multiceps (Leske, 1780) and their evaluation in sero-diagnosis*, *Vet Parasitol*, 11 (1982), 155–164.
- [7] A. Doganay, H. Oge, and G. Biyikoglu, *Serodiagnosis of coenurosis by ELISA in experimental infected lambs*, *Turkiye Parazitoloj Derg*, 23 (1999), 185–189.
- [8] M. L. Doherty, H. McAllister, and A. Healy, *Ultrasound as an aid to Coenurus cerebralis cyst localisation in a lamb*, *Vet Rec*, 124 (1989), 591.
- [9] G. T. Edwards and I. V. Herbert, *Observations on the course of Taenia multiceps infections in sheep: clinical signs and post-mortem findings*, *Br Vet J*, 138 (1982), 489–500.
- [10] K. A. el Sinnary, M. H. Tageldin, and H. S. al Sumry, *Outbreak of coenurosis (Taenia species) in Anglonubian goats in the Sultanate of Oman*, *Vet Rec*, 144 (1999), 296–297.

- [11] C. Ghazaei, *Evaluation of therapeutic effects of antihelminthic agents albendazole, fenbendazole and praziquantel against coenurosis in sheep*, Small Ruminant Res, 71 (2007), 48–51.
- [12] J. M. Gonzalo-Orden, A. Díez, J. R. Altónaga, J. M. Gonzalo, and M. A. Orden, *Computed tomographic findings in ovine coenurosis*, Vet Radiol Ultrasoun, 40 (1999), 441–444.
- [13] B. E. D. Hago and M. T. Abu-Samara, *A case of Multiceps gaigeri coenurosis in a goat*, Vet Parasitol, 7 (1980), 191–194.
- [14] M. B. Ing, P. M. Schantz, and J. A. Turner, *Human coenurosis in North America: case reports and review*, Clin Infect Dis, 27 (1998), 519–523.
- [15] J. Kaufmann, *Parasitic Infection of Domestic Animals*, Birkhäuser, Berlin, 1996.
- [16] A. Komnenou, S. Argyroudis, N. Giadinis, and A. Dessiris, *Surgical treatment of coenurosis (gid) in sheep*, Vet Rec, 147 (2000), 242–244.
- [17] T. Negita and A. Ito, *In vitro hatching of oncospheres of Taenia taeniaeformis using eggs isolated from fresh, frozen, formalin-fixed and ethanol-fixed segments*, J Helminthol, 68 (1994), 271–272.
- [18] M. Nooruddin, A. S. Dey, and M. A. Ali, *Coenurosis in Bengal goats of Bangladesh*, Small Ruminant Res, 19 (1996), 77–81.
- [19] P. Popesko, *Atlas of Topographical Anatomy of the Domestic Animals*, W. B. Saunders Co., Philadelphia, PA, 4th ed., 1984.
- [20] P. Popesko, B. Hájovská, V. Komárek, F. Marvan, and M. Vrzgulová, *Anatómia hospodárskych zvierat*, Príroda, Bratislava, 1992.
- [21] T. C. Price, M. H. Dresden, T. Alvarado, J. Flanagan, and C. L. Chappell, *Coenurosis in a spectacled langur (Presbytis obscura): praziquantel treatment and the antibody response to cyst antigens*, Am J Trop Med Hyg, 40 (1989), 514–520.
- [22] A. Scala, G. M. Cancedda, A. Varcasia, C. Ligios, G. Garippa, and C. Genchi, *A survey of Taenia multiceps coenurosis in Sardinian sheep*, Vet Parasitol, 143 (2007), 294–298.
- [23] D. Sharma and P. Chauhan, *Coenurosis status in Afro-Asian region: A review*, Small Ruminant Res, 64 (2006), 197–202.
- [24] G. C. Skerit, *Coenurosis*, in Diseases of Sheep, W. B. Martin and I. D. Aitken, eds., Blackwell Scientific Publications, Oxford, 2nd ed., 1991.
- [25] G. C. Skerit and M. F. Stallbaumer, *Diagnosis and treatment of coenurosis (gid) in sheep*, Vet Rec, 11 (1984), 399–403.
- [26] E. J. L. Soulsby, *Helminths, Arthropods and Protozoa of Domesticated Animals*, Bailliere Tindall, London, 1982.
- [27] Y. Takemoto, T. Negita, K. Ohnishi, M. Suzuki, and A. Ito, *A simple method for collecting eggs of taeniid cestodes from fresh, frozen or ethanol-fixed segments*, Int J Parasitol, 25 (1995), 537–538.
- [28] M. Tirgari, B. R. Howard, and A. Boargob, *Clinical and radiographical diagnosis of coenurosis cerebri in sheep and its surgical treatment*, Vet Rec, 120 (1987), 173–178.
- [29] F. Toofanian and B. Ivoghli, *Cerebral coenurosis in a wild sheep (Ovis ammon)*, J Wildl Dis, 12 (1976), 550–551.
- [30] G. M. Urquhart, J. Armour, J. L. Duncan, and F. W. Jennings, *Veterinary Parasitology*, Blackwell Publishing, Edinburgh, 2nd ed., 1996.
- [31] A. Varcasia, G. Tosceri, G. N. Coccone, A. P. Pipia, G. Garippa, A. Scala, et al., *Preliminary field trial of a vaccine against coenurosis caused by Taenia multiceps*, Vet Parasitol, 162 (2009), 285–289.
- [32] W. D. Vink, C. M. Lopes Pereira, A. Nota, and K. I. M. Balogh, *Prevalence of coenurosis in goats in Tete Province, Mozambique*, Ciencia e Técnica Veterinaria, 3 (1998), 29–34.
- [33] I. C. Wang, Y. X. Ma, C. H. Kuo, and P. C. Fan, *A comparative study on egg hatching methods and oncosphere viability determination for Taenia solium eggs*, Int Journal Parasitol, 27 (1997), 1311–1314.
- [34] J. M. Willis and I. V. Herbert, *A method for estimating the age of coenuri of Taenia multiceps recovered from the brains of sheep*, Vet Rec, 121 (1987), 216–218.