

Primary Adrenal Leiomyosarcoma in an Aged Japanese Woman: A Rare Case Report

Chie Aoki*, Seiichi Tanaka, Kunihiro Suzuki, Masaaki Sagara, and Yoshimasa Aso

Department of Endocrinology and Metabolism, Dokkyo Medical University, Mibu, Tochigi, Japan

*Corresponding author: Chie Aoki, Department of Endocrinology and Metabolism, Dokkyo Medical University, Mibu, Tochigi, Japan, Tel: +81282872150; Fax: +81282864632; E-mail: c-aoki@dokkyomed.ac.jp

Rec date: Feb 13 2017; Acc date: Mar 16, 2017; Pub date: Mar 22, 2017

Copyright: © 2017 Aoki C, et al. This is an open-access article distributed under the terms of the Creative Commons Attribution License, which permits unrestricted use, distribution, and reproduction in any medium, provided the original author and source are credited.

Abstract

Primary adrenal leiomyosarcoma is an extremely rare tumor. Here, we report the case of a primary adrenal leiomyosarcoma in an 81-year-old woman. Computed tomography showed a right adrenal tumor (7 cm). There were no abnormal findings on physical examination and her serum adrenal hormone levels were normal. However, 67Gallium scintigraphy showed gallium accumulation at the site of a right adrenal tumor, and malignancy was suspected. The right adrenal tumor was surgically removed and histological examination revealed that it was a leiomyosarcoma. After surgical treatment, the patient was administered different types of chemotherapy but she died of local recurrence 1 year later.

Keywords: Adrenal tumor; Adrenal Leiomyosarcoma; Malignancy

Introduction

Leiomyosarcoma is a rare malignant tumor that occurs in the retroperitoneum, uterus, and the gastrointestinal tract. Primary adrenal leiomyosarcoma is an extremely rare disease and approximately only 30 cases, including our case, have been reported in and outside Japan since it was first described in 1981 [1,2]. Here, we report a case with the final diagnosis of primary adrenal leiomyosarcoma.

Case Report

The subject patient was an 81-year-old woman. She visited a local clinic because of abdominal discomfort in February 2012. Since an abdominal ultrasound showed a mass lesion adjacent to the liver, the patient was referred to our hospital (Dokkyo medical University,

Tochigi, Japan) for examination. An abdominal computed tomography scan revealed an adrenal tumor (approximately 7 cm). Therefore, the patient was referred to our department and hospitalized for examination.

The patient's vital signs on admission were height: 144.8 cm, weight: 42.15 kg, body temperature: 36.5°C, blood pressure: 135/66 mmHg, heart rate 72/min, and a normal sinus rhythm. No clear abnormal physical findings or signs of Cushing's syndrome were observed.

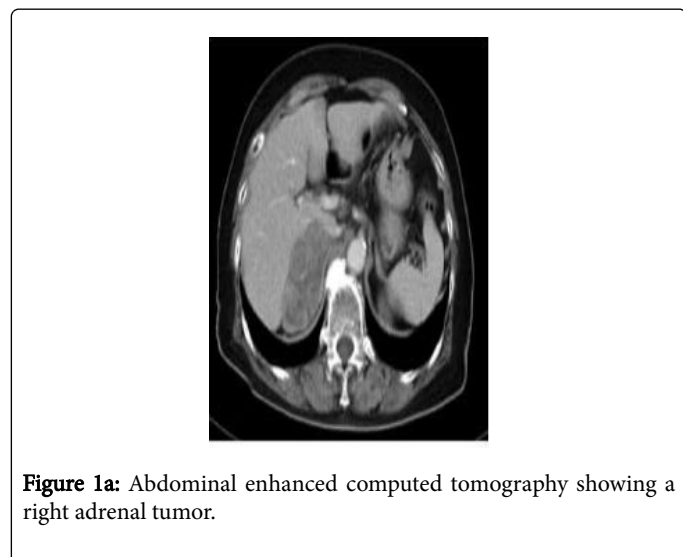
A blood test demonstrated a sodium level of 126 mEq/L, which indicated hyponatremia. Electrolyte imbalance or abnormal blood counts were not observed. Although adrenocorticotropic hormone levels were high (162.0 pg/mL), cortisol levels (19.5 µg/mL) were within the normal range and excessive production of corticosteroids/adrenal medullary hormones was not observed. In regards to tumor markers, the levels of neuron-specific enolase and interleukin 2 receptor and thymidine kinase activity were elevated (Table 1).

Blood cell count	Tumor marker	Adrenal gland hormone
WBC 6300/µL	CEA 1.0 ng/mL	Time
RBC 401 × 10 ⁴ /µL	NSE47.0 ng/mL	06:00 CS 19.5 µg/mL ACTH 162.0 pg/mL
Hb 11.7 g/dL	CA19-93 IU/mL	22:00 CS 5.7 µg/mL ACTH 7.8 pg/mL
Ht 34.6%	IL-2 receptor720 U/mL	Urinary free cortisol 16.5 µg/day
Plt 31.8 × 10 ⁴ /µL	Thymidine kinase activity 11 U/L	DHEA-S 70 µg/dL (Catecholamine)
Biochemistry	Pituitary hormone	Adrenaline: 0.03 ng/mL
AST 19 IU/L	GH 0.1 ng/mL	Noradrenaline: 0.50 ng/mL
ALT 9 IU/L	LH 30.80 mIU/mL	Dopamine: 0.02 ng/mL
ALP 167 IU/L	FSH 80.00 mIU/mL	(24 hour Urinary Catecholamine)

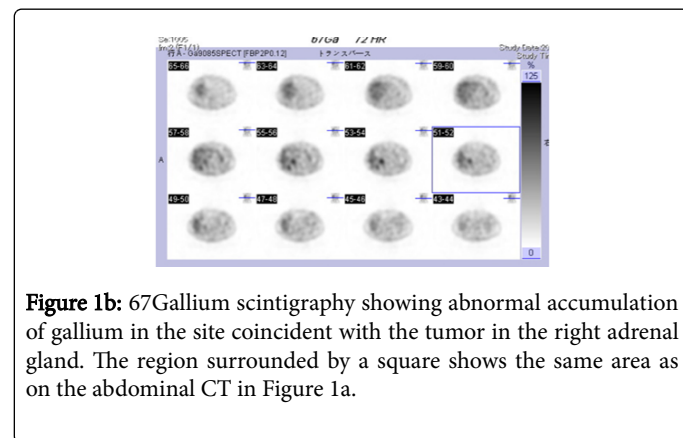
LDH 191 IU/L	PRL 13.30 ng/mL	Adrenaline: 6.9 µg/day
T-Bil 0.4 mg/dL	TSH 3.40 µIU/mL	Noradrenaline: 106 µg/day
BUN 16 mg/dL		Dopamine: 430 µg/day
Cre 0.82 mg/dL	Thyroid hormone	(24 hour Urinary Metanephrine)
Na 126 mEq/L	F-T4 1.3 ng/dL	Metanephrine: 0.09 mg/day
K 4.6 mEq/L	F-T3 2.9 pg/dL	Normetanephrine: 0.24 mg/day
Cl 88 mEq/L		Total metanephrine: 0.33 mg/day
Glu 98 mg/dL		

Table 1: Laboratory data on admission.

An abdominal contrast-enhanced computed tomography scan revealed a mass lesion ≤ 7 cm in the right adrenal gland that was non-uniformly enhanced, findings suggestive of an adrenal carcinoma (Figure 1a).

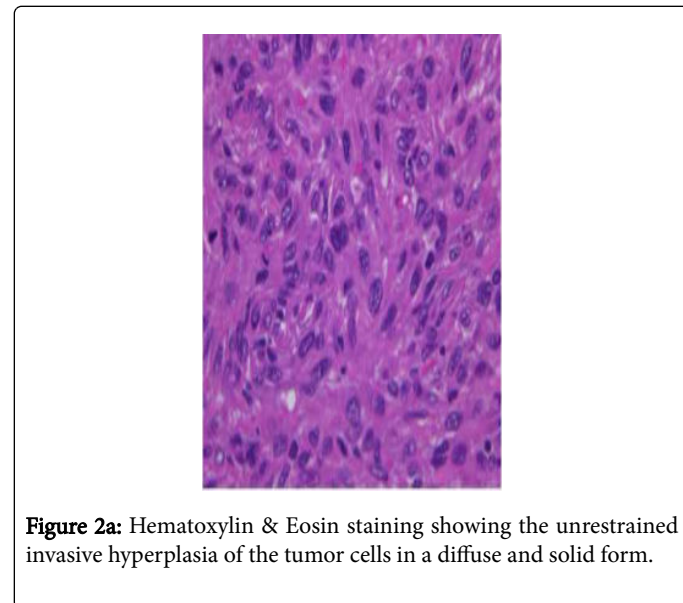


surgery, a computed tomography scan 2 months after surgery revealed a local recurrence. Therefore, the patient was readmitted to the Department of Urology. The treatment was changed to Sunitinib at 25 mg/day three months after surgery.



⁶⁷ Gallium scintigraphy demonstrated abnormal accumulation of gallium in the site coincident with the tumor in the right adrenal gland, which is consistent with findings caused by malignancy. Thus, we believed it might be a malignant tumor in the right adrenal gland (Figure 1b). Because surgical treatment was indicated for this case, the patient underwent a translumbar right adrenalectomy in our Department of Urology.

Postoperative pathological examination revealed the following findings: unrestrained invasive hyperplasia of the tumor cells in a diffuse and solid form, atypical spindle cells with oval-shaped nuclei growing in a flowing sequence (Figure 2a). Positive immunostaining results for specific smooth muscle actin and vimentin (Figure 2b). Therefore, the tumor was believed to be a smooth muscle-derived tumor and the patient was diagnosed with adrenal leiomyosarcoma. Postoperative chemotherapy was initiated using mitotane at 500 mg/day. However, mitotane was discontinued after 1 month because adrenal carcinoma was ruled out based on pathological test results. Although ambulatory chemotherapy had been continued using a tegafur-uracil compound agent 200 mg/day since, 1 month after



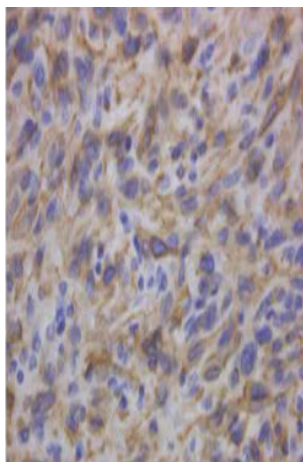


Figure 2b: Positive smooth muscle actin immunostaining (40× magnification).

However, the tumor recurred locally, invaded the liver, and continued to grow further. Six months after surgery, the treatment was modified to everolimus at 5 mg/day, but its administration was discontinued 1 month later due to the side effect of stomatitis.

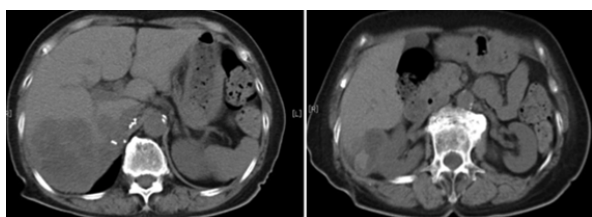


Figure 3: Computed tomography 1 year after surgery.

A computed tomography scan 8 months after surgery showed further growth of the tumor, and treatment with Axitinib at 10 mg/day was initiated. Ten months after surgery, a computed tomography scan demonstrated that the tumor had grown to 140 mm × 132 mm. Extensive necrosis and bleeding were observed inside the tumor, but the treatment had been continued because of the effective pain relief it provided (Figure 3).

One year after surgery, in April 2013, the patient's general condition deteriorated. In May, the patient was hospitalized because of pneumonia and anasarca. However, treatment with antibiotics and diuretics was not effective and the patient died of respiratory failure.

A pathological autopsy was performed with the family's permission to further investigate the cause of death. The autopsy indicated that the direct cause of death was adrenal leiomyosarcoma.

Discussion

As stated above, primary adrenal leiomyosarcoma is an extremely rare disease among leiomyosarcomas, with only approximately 30 cases reported in and outside Japan. Most patients with primary adrenal leiomyosarcoma are older and develop a large tumor.

Primary adrenal leiomyosarcoma is believed to develop from the smooth muscle layer of the central vein and its branch veins. Some studies have reported an association with HIV infection and the Epstein-Barr virus infection, and the possibility of a viral infection etiology has been suggested [3-5].

Primary adrenal leiomyosarcoma is characteristic in that in spite of the fast growth of the tumor itself, due to its presence in the retroperitoneal space, subjective symptoms do not usually occur. Because the tumor does not produce hormones, it is not detected until it grows to a huge size. Therefore, primary adrenal leiomyosarcoma is frequently identified due to symptoms such as abdominal pressure and pain caused by the enlarged tumor [6-8].

Since no specific tumor markers for leiomyosarcoma or characteristic imaging findings that allow diagnosis are available, a definite diagnosis is difficult preoperatively. Thus, definitive diagnosis does not occur until after histopathological examination.

In all reported cases, the final diagnosis was reached only after surgery or autopsy. However, one of these cases exhibited elevated neuron-specific enolase levels. The authors of the report suggested that since the plasma neuron-specific enolase levels decreased to the normal range after surgery, an association exists between neuron-specific enolase and primary adrenal leiomyosarcoma, which may allow neuron-specific enolase levels to be used for early detection or as a diagnostic marker. Although we observed elevated neuron-specific enolase levels in our patient, a case without elevated neuron-specific enolase has also been reported [8]. Therefore, more cases and further studies are necessary.

Surgical resection is the basic approach to treating retroperitoneal soft tissue sarcomas. However, a study reported that even when combined resection of surrounding organs was performed, approximately 50% of soft tissue sarcoma cases showed local recurrence and 20% to 30% cases were found to have distant metastasis [9]. The mainstay of treatment is early diagnosis. The survival rate depends on the tumor size and its site of development. Most cases are progressive and the prognosis is extremely poor. Therefore, surgical treatment alone is not sufficient and simultaneous adjuvant therapy is frequently performed [10].

Chemotherapy and radiation therapy are effective adjuvant therapies that destroy and decrease the growth of tumor cells [11]. Some studies have reported that radiation therapy is particularly important in cases where a large tumor locally redevelops or a tumor is located at a site that makes its complete removal difficult [12-14].

Doxorubicin and ifosfamide have been the most effective chemotherapy for soft tissue sarcomas in monotherapy and combination therapy for the past 4-5 years. In addition, taxanes and, in particular, for leiomyosarcoma, gemcitabine plus taxane combination therapy and a new drug, trabectedin, are effective [15]. The molecular targeted drugs Sunitinib, Cediranib, and Sorafenib, and the mammalian target of rapamycin inhibitors appear to be effective for some soft tissue sarcomas. Pazopanib, in particular, is effective for leiomyosarcoma [15].

Due to the preoperative suspicion of adrenal gland cancer, mitotane was administered immediately after the operation until the pathological diagnosis was established. However, the patient underwent postoperative chemotherapy. Once adrenal leiomyosarcoma was confirmed as the pathological diagnosis, we administered Sunitinib, everolimus, and Axitinib for treatment.

Although the drugs used in this case were different from those used in chemotherapy regimens described earlier, both Sunitinib and everolimus have been reported to be effective for subtypes of soft tissue sarcoma. In particular, Sunitinib has been used in a phase II study to target the soft tissue sarcoma subtypes leiomyosarcoma, liposarcoma, and malignant fibrous histiocytoma, and it is expected to be effective for the treatment of leiomyosarcoma [15,16]. We ultimately used Axitinib in the current case because of the adverse effects caused by other drugs, rendering them unusable. The patient received an explanation that Sunitinib, everolimus, and Axitinib are not covered under health insurance for the treatment of leiomyosarcoma, and the drugs were administered with the patient's consent.

As mentioned above, there is no established method for the treatment of adrenal leiomyosarcoma; therefore, for postoperative chemotherapy, the patient was administered a number of molecular targeted drugs that were not covered by Japanese health insurance but that may have some effect on soft-tissue tumors. However, localized recurrence developed and the patient survived for only 1 year postoperatively. Radiotherapy was not used in this case, but its use in cases of localized recurrence has been reported to be effective. It is possible that its use in addition to chemotherapy should also have been considered in the treatment of our patient [12-14].

Thus, in leiomyosarcoma, a poor prognosis is common even when surgical treatment and chemotherapy/radiation therapy are administered. On the other hand, survival for over 2 years has been reported when a tumor recurrence after a radical operation was treated with radiation/chemotherapy [17]. Another recent study showed that the survival rates in all patients were significantly improved by the microtubule inhibitor, Eribulin, as compared to dacarbazine, which has been used as an effective drug for leiomyosarcoma [18]. Thus, an improvement in prognosis can be expected with advances in drug development.

References

1. Choi SH, Liu K (1981) Leiomyosarcoma of the adrenal gland and its angiographic features: A case report. *J Surg Oncol* 16: 145-148.
2. Nakaishi M, Iseda T, Nishio S, Yokoyama M (1999) Spontaneous retroperitoneal hemorrhage from an adrenal leiomyosarcoma: A case report. *Nishinohon J Urol* 61: 465-467.
3. Lack EE (1997) Tumors of the adrenal gland and extra-adrenal paraganglioma. *Atlas of Tumor Pathology*. (3rd edn, fascicle 19), Armed Forces Institute of Pathology, Washington DC. p. 184-187.
4. Suankratay C, Shuangshoti S, Mutirangura A, Prasanthai V, Lerdlum S, et al. (2005) Epstein-Barr virus infection associated smooth-muscle tumors in patients with AIDS. *Clin Infect Dis* 40: 1521-1528.
5. Zhou Y, Tang Y, Tang J, Deng F, Gong G, et al. (2015) Primary adrenal leiomyosarcoma: A case report and review of literature. *Int J Clin Exp Pathol* 8: 4258-4263.
6. Wong C, Von Oppell UO, Scott-Coombes D (2005) Cold feet from adrenal leiomyosarcoma. *J Royal Soc Med* 98: 418-420.
7. Matsui Y, Fujikawa K, Oka H, Fukuzawa S, Takeuchi H (2002) Adrenal leiomyosarcoma extending into the right atrium. *Int J Urol* 9: 54-56.
8. Kato T, Sakamoto S, Kobayashi T, Ikeda R, Nakamura T, et al. (2004) Primary adrenal leiomyosarcoma with inferior vena cava thrombosis. *Int J Clin Oncol* 9:189-192.
9. Mendenhall WM, Zlotecki RA, Hochwald SN, Grobmyer SR, Cance WG (2005) Retroperitoneal soft tissue sarcoma. *Cancer* 104: 669-675.
10. Zhou Y, Tang Y, Tang J, Deng F, Gong G, et al. (2015) Primary adrenal leiomyosarcoma: A case report and review of literature. *Int J Clin Exp Pathol* 8: 4258-4263.
11. Strander H, Turesson I, Cavallin-Stahl E (2003) A systematic overview of radiation therapy effects in soft tissue sarcomas. *Acta Oncol* 42: 516-531.
12. van Etten B, van Ijken MGA, Mooi WJ, Oudkerk M, van Geel AN (2001) Primary leiomyosarcoma of the adrenal gland. *Sarcoma* 5: 95-99.
13. Deshmukh SD, Babanagare SV, Anand M, Pande DP, Yavalkar P (2013) Primary adrenal leiomyosarcoma: A case report with immunohistochemical study and review of literature. *J Cancer Res Ther* 9: 114-116.
14. Goto J, Otsuka F, Kadera R, Miyoshi T, Kinomura M, et al. (2008) A rare tumor in the adrenal region: Neuron-specific enolase (NSE)-producing leiomyosarcoma in an elderly hypertensive patient. *Endocr J* 55: 175-181.
15. Papai Z (2014) Medical treatment of soft tissue sarcomas based on the historical subtype. *Magy Onkol* 58: 53-58.
16. Mahmood ST, Agresta S, Vigil CE, Zhao X, Han G, et al. (2011) Phase II study of sunitinib malate, a multitargeted tyrosine kinase inhibitor in patients with relapsed or refractory soft tissue sarcomas. Focus on three prevalent histologies: Leiomyosarcoma, liposarcoma and malignant fibrous histiocytoma. *Int J Cancer* 8: 1963-1969.
17. Candanedo-Gonzalez FA, Vela Chavez T, Cerbulo-Vazquez A (2005) Pleomorphic leiomyosarcoma of the adrenal gland with osteoclast-like giant cells. *Endocr Pathol* 16: 75-81.
18. Schoffski P, Chawla S, Maki RG, Italiano A, Gelderblom H, et al. (2016) Eribulin versus dacarbazine in previously treated patients with advanced liposarcoma or leiomyosarcoma: A randomized, open-label, multicentre, phase 3 trial. *Lancet*.