

Puumala Virus Pulmonary Syndrome with Multi Organ Failure in Southern Austria

Sonja M Kielhauser¹, Thomas Valentin², Robert Krause², Heike Mitterhammer³, Stephan W Aberle⁴, Kurt Weber¹, Winfried B Graninger¹ and Florentine C Moazed-fuerst¹

¹Division of Rheumatology and Immunology, Department of Internal Medicine, Medical University of Graz, Austria

²Section of Infectious Diseases, Division of Pulmonology, Department of Internal Medicine, Medical University of Graz, Austria

³Medical Intensive Care Unit, Department of Internal Medicine, Medical University of Graz, Austria

⁴Department of Virology, Medical University of Vienna, Austria

Corresponding author: Florentine C Fuerst, Medical University Graz, Division of Rheumatology and Immunology Medical University of Internal Medicine Auenbruggerplatz 15, A-8036 Graz, Austria, Tel: 004331638517779; E-mail: Florentine.fuerst@medunigraz.at

Rec date: Apr 16, 2014; **Acc date:** Jun 27, 2014; **Pub date:** Jun 30, 2014

Copyright: © 2014 Kielhauser SM, et al. This is an open-access article distributed under the terms of the Creative Commons Attribution License, which permits unrestricted use, distribution, and reproduction in any medium, provided the original author and source are credited.

Keywords: Hantaviruses; Europe; Myalgias; Temperature

Case Report

European Hantaviruses such as Puumala virus (PUUV) usually cause Hemorrhagic Fever with Renal Syndrome (HFRS). Fatal progression of Hantavirus Pulmonary Syndrome (HPS) is rarely reported from Europe.

Hantaviruses are transmitted by inhalation of viral particles from rodent's urine, saliva and excrements. Within Austria, most Puumala virus cases are reported from special areas in the southern provinces of Styria and Carinthia. HPS is usually encountered in the Americas, but recently a small case series from Sweden has been reported [1].

Some Cases are reported from Belgium and Finland [2]. A successful therapy was reported by Antonen et.al. with a bradykinin receptor antagonist icatiband [2,3].

A 64 year old female patient without any previous health impairment presented to the emergency room in June 2011 because of a two-day history of fever, myalgias and headache. She was retired, had no pets and there was no history of travel in the past few years.

Three days before symptom onset, she had cleaned her old garden house and filled sandbags. There was no history of direct mouse or rodent contact.

On admission, the temperature was 40°C. Chest radiograph did not show any abnormalities. The laboratory results are shown in Table 1. The point-of-care Puumala IgM rapid test (Reagent International Ltd., Toivala, Finland) was positive on two occasions. Puumala Virus IgG and IgM antibodies were confirmed by the strip-immunoassay recomLine Bunyavirus IgG/IgM (Mikrogen, Neuried, Germany). Virus nucleic acid was detected by a nested PCR in the peripheral blood, and sequence analyses of the 278bp long amplicon within the G2 protein coding region of the Hantavirus M-segment confirmed that the infection was caused by Puumala Virus [4].

	Normal range	Day 1	Day 2	Day 4
Leucocyte Count (x10 ⁹ /L)	4.4-11.3	12.4	16.4	54.3
Haemoglobin (g/dL)	12.0-15.3	14.6	16.3	8.8
Platelets (x10 ⁹ /L)	140-440	108	37	18
Creatinine (mg/dL)	0.5-1.0	0.91	0.96	2.17

Prothrombin Time (%)	70-120	103	107	7
PZ INR	0-1	0.89	0.98	6.11
D DIM (mg/l)	-0.5		3,9	4
Antithrombin 3 (%)	>75	88	76	9
Fibrinogen (mg/dL)	210-400	473	399	<80
C-Reactive Protein (mg/L)	-5	67	125	97
Procalcitonin (ng/mL)	-0.5	1.26	2.06	4.16
Lactate (mmol/L)	0.5-2.2	1.1	2.1	12.1

Table 1: Laboratory results during the course

One day after admission, she developed a dry cough. A thoracic CT scan revealed bilateral interstitial and alveolar infiltrates progressing within 24 hours (Figure 1).

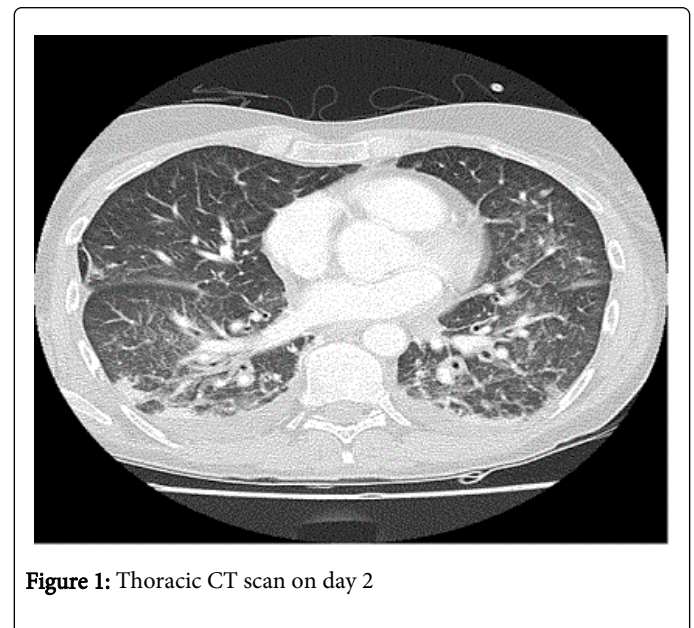


Figure 1: Thoracic CT scan on day 2

Because of the high grade dyspnoea and respiratory failure the patient was transferred to the intensive care unit and required mechanical ventilation. A Bronchoalveolar Lavage (BAL) was done

and PCR for CMV, EBV, influenza, mycoplasma pneumoniae, chlamydia pneumoniae and mycobacteria were negative from BAL fluid. Bacterial and fungal cultures yielded no growth. Urine antigen tests for legionella and streptococcus pneumoniae were negative. PCR for Puumala virus from BAL was positive. The patient developed disseminated intravascular coagulopathy (the blood results are shown in Table 1) with inner organ bleeding in the lung and in the spleen, these facts are discovered in the autopsy results.

The patient also developed a renal failure with anuria <200 ml urine (a renal replacement therapy had not been started because of the rapid clinical break up) and hypotension (initial 75/60 mmHG) despite high dose catecholamine treatment.

The patient died from refractory shock with multi organ failure on day four after admission.

Our patient met the CDC case definition for HPS [5].

Sporadic outbreak of hantavirus pulmonary syndrome in the United States and in Europe have been described in the literature over the past years [2,3,6,7]. In these reported cases, the rapid progression to respiratory failure has not been reported. Only few similar cases have been reported, including a case series of 3 patients from Sweden and 2 patients with multi organ failure from Austria reported in 2003 and 2006 [1,7] respectively.

Hantaviruses belong to the family Bunyaviridae. They are human pathogens that are prevalent worldwide [5]. In western and central Europe, the predominant serotype is the Puumala virus, which usually causes nephropathia epidemica. Progressive pulmonary insufficiency associated with Puumala virus infection has rarely been reported from Europe, while pulmonary symptoms are common, but these have been attributed to fluid overload. Our case illustrates that European Hantaviruses such as Puumala virus can cause HPS with multi organ failure. The incidence of HPS and multi organ failure due to Puumala virus is unknown.

European Hantaviruses should be taken into consideration for the differential diagnosis of acute respiratory distress and fever in epidemic areas since a successful therapy option with a bradykinin receptor antagonist has been reported by a patient with severe capillary leakage syndrome caused by puumala hantavirus infection.

The mechanism of the new treatment is not so clear so far, but it probably increases the capillary leakage. Just a single dose of the bradykinin receptor showed a dramatic positive response [3].

Competing Interests:

There are no competing interests.

Author's contributions:

Kielhauser SM-Data acquisition, manuscript preparation; Valentin T-Data acquisition, manuscript preparation; Krause R-Data discussion; Mitterhammer H-Patient treatment; Aberle S-Technical support; Weber K-Data acquisition; Fuerst FC-Data acquisition, manuscript preparation; Graninger WB-manuscript preparation, supervision

References

1. Rasmuson J, Andersson C, Norrman E, Haney M, Evander M, et al. (2011) Time to revise the paradigm of hantavirus syndromes? Hantavirus pulmonary syndrome caused by European hantavirus. *Eur J Clin Microbiol Infect Dis* 30: 685-690.
2. Gizzi M, Delaere B, Weynand B, Clement J, Maes P, et al. (2013) Another case of European hantavirus pulmonary syndrome with severe lung, prior kidney involvement, and diagnosed by viral inclusions in lung macrophages. *Eur J Clin Microbiol Infect Dis* 32: 1341-1345.
3. Antonen J, Leppänen I, Tenhunen J, Arvola P, Mäkelä S, et al. (2013) A severe case of Puumala hantavirus infection successfully treated with bradykinin receptor antagonist icatibant. *Scand J Infect Dis* 45: 494-496
4. Nichol ST, Spiropoulou CF, Morzunov S, Rollin PE, Ksiazek TG, et al. (1993) Genetic identification of a hantavirus associated with an outbreak of acute respiratory illness. *Science* 262: 914-917
5. Anonymous Hantavirus pulmonary syndrome (HPS) case definition. Atlanta: Centers for Disease Control and Prevention (CDC).
6. Launay D, Thomas Ch, Fleury D, Roueff S, Line ML, et al. (2003) Pulmonary-renal syndrome due to hemorrhagic fever with renal syndrome: an unusual manifestation of puumala virus infection in France. *Clin Nephrol* 59: 297-300.
7. Krause R, Aberle S, Haberl R, Daxböck F, Wenisch C (2003) Puumala virus infection with acute disseminated encephalomyelitis and multiorgan failure. *Emerg Infect Dis* 9: 603-605.