

Severe GERD with Non Resolving Pneumonia Requiring Surgical Intervention for Survival

Harish GV^{*} and Srujan K

Prathima Institute of Medical Sciences, Karimnagar, India

^{*}Corresponding author: Harish GV, Assistant Professor, Prathima Institute of Medical Sciences, Karimnagar, India, Tel: 9581618151; E-mail: drharish82@gmail.com

Received date: April 11, 2017; Accepted date: April 17, 2017; Published date: April 26, 2017

Copyright: © 2017 Harish GV, et al. This is an open-access article distributed under the terms of the Creative Commons Attribution License, which permits unrestricted use, distribution, and reproduction in any medium, provided the original author and source are credited.

Abstract

Infant reflux becomes evident in the first few months of life, peaks at 4 months and resolves in up to 88% by 12 months and in nearly all by 24 months. Infantile reflux manifests more often with regurgitation, signs of esophagitis and resulting failure to thrive. We report the case of two months old male child with GERD with non-resolving pneumonia only relieved after surgical intervention.

Introduction

Gastroesophageal reflux is defined as the passage of stomach contents into the esophagus with or without regurgitation (spitting up) and vomiting. It is a normal physiologic process that occurs throughout the day in infants and less often in children and adolescents [1].

For healthy infants, GER episodes usually occur postprandial and last for less than three minutes. To pediatricians, the most noticeable symptom is regurgitation occurring daily with most infants aged less than three months. This symptom is usually resolved by the age of 12 months. The disease that might develop secondary to persistent GER is referred as GERD. To avoid diagnostic testing and unwanted medication, determining GERD from GER is essential.

Case Report

A two months old male child presented with fever, vomiting, cough, difficulty in work of breathing and one episode of seizure. Child had a past history of pneumonia 1 month back and admitted in a private hospital for 10 days. Birth history of child was nil significant. On examination, there was pallor and generalized rash with blanching over the body. Downes score observed was 7/10 [RR: 78, Audible grunt, severe retractions]. The following vitals were recorded, Temperature: 100°F, Pulse: 160/minute, Respiratory rate: 78/minute and SPO₂: [2] 81% with O₂. As the respiratory distress was severe, child was intubated and connected to mechanical ventilator. Child was started with IV fluids, antibiotics [IN]. Meropenem, Vancomycin, Netilmicin, Antiviral [IN]. Acyclovir, antiepileptics and other symptomatic medications were administered. Child was investigated with CBP showing microcytic hypochromic anemia with relative neutrophilia and reactive thrombocytosis (Figure 1).

All other routine investigations were normal, X-Ray chest showing homogenous opacification in upper and middle lobes and air space filling with numerous air bronchograms (Figure 2). All other investigation were normal [3]. USG Abdomen done which showed grade IV GER. Child was further investigated with X-Ray gastrograffin swallow in view of recurrent cough and regurgitation showing Grade IV GE reflux (Figure 3). Paediatric surgeon opinion was taken who suggested GER surgery and child was posted for surgery. In view of

low Hb levels 1 unit of PRBC was given and laparoscopic fundoplication was done under GA. Post operatively child was shifted to PICU and kept for NBM for 48 h (given NG feeds) later allowed oral feeds for which child tolerated well and was observed for 48 h Post-surgery, child was accepting feeds well with no history of any cough and regurgitation of food contents.

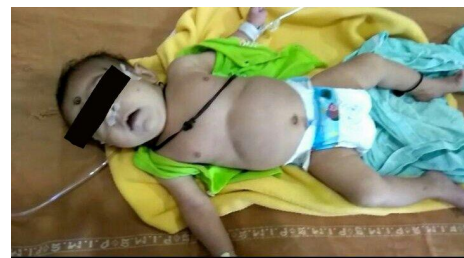

Figure 1: The figure shows the severe intercostal retractions.

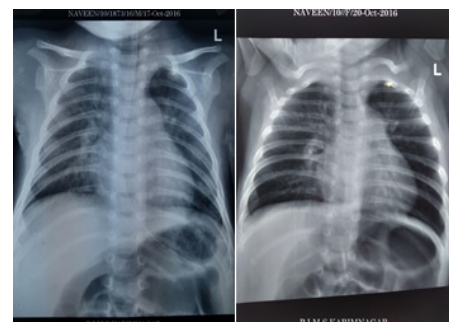


Figure 2: Homogenous opacification in upper and middle lobes and air space filling with numerous air bronchograms.

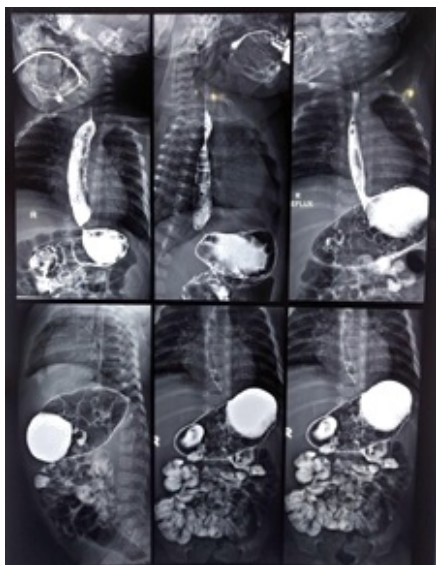


Figure 3: Gastrografin X-Ray showing grade IV GE reflux.

Discussion

The symptom of gastroesophageal reflux reported by parent of the infant is the primary diagnosis for GERD. Frequent regurgitation, frequent vomiting, postprandial irritability, feeding refusal, prolonged feeding, indicates to Infantile gastroesophageal reflux [4,5].

Immediate imaging is required in the case of progressive worsening projectile vomiting for infants in the first few months. In some cases, surgical referral is seldom suggested. Either GERD or more concerning Pathology is suggested in the case of Regurgitation or recurrent vomiting beyond eighteen months. Few other symptoms leaning to GERD are poor weight gain, abdominal pain reported by parent, choking or coughing while feeding. In the first few months, bilious vomiting might suggest intestinal obstruction. Further workup is required for Gastrointestinal bleeding [6-8]. In some cases, infantile torticollis is caused from sandifer syndrome (lateral head tilt alongside contralateral chin rotation), which could attribute to GERD.

Choking, change in muscle tone, apnea, color change are common attributes to GERD, lower respiratory tract infection and seizures. Hospitalization and thorough investigation is required before diagnosing the above symptoms as GERD.

If symptoms still prevail after acid suppression therapy, treatment failure should be evaluated by diagnostic testing. These atypical symptoms can then be attributed to GERD and we can exclude other possibilities upon diagnostic testing. Upper endoscopy with biopsy is considered when reflux does not respond to initial treatments [9]. It is the principal method of evaluating the esophageal mucosa for complications of GERD and excluding other possible causes, such as eosinophilic esophagitis, esophageal webs, and infectious esophagitis. Esophageal pH monitoring is the most widely used test to quantify the frequency of reflux over 24 h using the reflux index. Increasingly, pH monitoring is combined with multiple intraluminal impedance to evaluate GERD [2,4]. Multiple intraluminal impedance plus pH monitoring is considered superior to pH monitoring alone because it can differentiate acidic, weakly acidic, or nonacidic reflux; identify

solid, liquid, or gas reflux; and better determine the temporal correlation between reflux and atypical symptoms. The high cost, high inters observer variability, and the lack of well-designed studies supporting its diagnostic accuracy limit its use [10].

A barium study (upper gastrointestinal series) is useful for evaluating for anatomic causes of symptoms, particularly dysphagia and odynophagia, and bilious vomiting. It should not routinely be used to diagnose GERD or assess its severity [11].

For severe GERD cases with unsuccessful medical therapy or non-tolerable medical therapy, surgical treatments options are available and are often considered. These options include complete or partial Nissen fundoplication. Newer endoscopic approaches performed in adults have been studied in children. Surgical treatments have significant risk of reflux recurrence and should be considered carefully.

Conclusion

GERD in infants mostly present with gastrointestinal symptoms (regurgitation, vomiting's, Failure to Thrive) but in some cases with severe GERD may present with recurrent respiratory tract infections (in this case with respiratory distress, and non-resolving pneumonia which requiring surgery for survival). To reduce morbidity and avoid more serious complications, attention must be given to early recognition of severe GERD and its surgical management.

References

1. National Collaborating Centre for Women's and Children's Health (2015) Gastro-oesophageal reflux disease: Recognition, diagnosis and management in children and young people. National Institute for Health and Care Excellence. London, UK.
2. Sherman PM, Hassall E, Fagundes-Neto U, Gold BD, Kato S, et al. (2009) A global, evidence based consensus on the definition of gastroesophageal reflux disease in the pediatric population. *Am J Gastroenterol* 104: 1278-1295.
3. Vandenplas Y, Rudolph C, Di Lorenzo C, Hassall E, Liptak G, et al. (2009) Pediatric gastroesophageal reflux clinical practice guidelines: joint recommendations of NASPGHAN and ESPGHAN. *J Pediatr Gastroenterol Nutr* 49: 498-547.
4. Tolia V, Vandenplas Y (2009) Systematic review: the extra-oesophageal symptoms of gastro-oesophageal reflux disease in children. *Aliment Pharmacol Ther* 29: 258-272.
5. American College of Radiology (2014) ACRSPR practice parameter for the performance of contrast esophagrams and upper gastrointestinal examinations in infants and children. Society for Pediatric Radiology. Resolution 39.
6. Marlais M, Fishman JR, Fell JME, Haddad MJ, Rawat DJ (2011) UK incidence of achalasia: an 11-year national epidemiological study. *Arch Dis Child* 96: 192-194.
7. Horvath A, Dziechciarz P, Szajewska H (2008) The effect of thickened-feed interventions on gastroesophageal reflux in infants: systematic review and meta-analysis of randomized, controlled trials. *Pediatrics*. 122.
8. Cafarotti A, Bascietto C, Salvatore R, Breda L, Chiarelli F, et al. (2014) A 6-month-old boy with uncontrollable dystonic posture of the neck. Sandifer syndrome. *Pediatr Ann* 43: 17-19.
9. Guarino A, Albano F, Ashkenazi S, Gendrel D, Hoekstra JH, et al. (2008) European Society for Paediatric Gastroenterology, Hepatology, and Nutrition/European Society for Paediatric Infectious Diseases evidence-based guidelines for the management of acute gastroenteritis in children in Europe: executive summary. *J Pediatr Gastroenterol Nutr* 46: 619-621.
10. Wenzl TG, Benninga MA, Loots CM, Salvatore S, Vandenplas Y (2012) Indications, methodology, and interpretation of combined esophageal

-
- impedance-pH monitoring in children: ESPGHAN EURO-PIG standard protocol. *J Pediatr Gastroenterol Nutr* 55: 230-234.
11. Orenstein SR (2010) Symptoms and reflux in infants: Infant Gastroesophageal Reflux Questionnaire Revised (I-GERQ-R)-utility for symptom tracking and diagnosis. *Curr Gastroenterol Rep* 12: 431-436.