

Testicular Epidermoid Cyst: A Case Report

Khadijeh Abdal¹ and Mohammadreza Hafezi Ahmadi^{2*}

¹Department of Oral and Maxillofacial Pathology, Ilam University of Medical Sciences, Ilam, Iran

²Department of Pathology, Ilam University of Medical Sciences, Ilam, Iran

*Corresponding author: Mohammadreza Hafezi Ahmadi, Department of Pathology, Ilam University of Medical Sciences, Ilam, Iran, Email: fariba4479@yahoo.com

Received date: June 04, 2018; Accepted date: June 14, 2018; Published date: June 21, 2018

Copyright: ©2018 Abdal K, et al. This is an open-access article distributed under the terms of the Creative Commons Attribution License, which permits unrestricted use, distribution, and reproduction in any medium, provided the original author and source are credited.

Abstract

Epidermal cysts are the most common skin benign epithelial cysts. Most epidermal cysts occur in the skin of the head, neck, ear, face, and back. Testicular epidermoid cyst is very rare. We presented a 70-year-old man with testicular epidermoid cyst in this report.

Keywords: Epidermoid cyst; Testis; Benign epithelial cysts

Introduction

Most epidermoid cysts are derived from the follicular infundibulum and also are called in infundibular cysts [1]. These cysts have non-malignant potential and metastasis [2]. The first case report for testicular epidermoid cyst was published by Dockerty and Priestly in 1942 [3]. Here in this case report we have presented a rare testicular benign epidermoid cyst.

Case Presentation

70-year-old man was referred to hospital with the complaints of left testicular pain. In clinical examination, left testis was found as a palpable hard nodule. Right testis was completely normal. Patient had no past history and trauma. Evaluated laboratory tests showed no abnormal findings. Serum alpha-fetoprotein, beta-HCG and LDH were between normal range limits. Ultrasonography showed left testis larger than the right testis. Lesion was present in testicular parenchyma without invasion into the capsule.

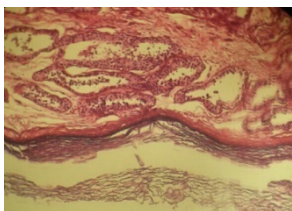


Figure 1: Histologically, the cystic lesion lined by stratified squamous epithelium with a prominent granular cell layer. The cyst lumen is filled with the abundant keratin. (H&E magnification X20).

According to clinical and radiographic finding evaluation we diagnosed an initial testicular tumour primarily. The patient underwent orchiectomy of the testicular mass. Then, we performed a frozen section to rule out surgical margins malignancy. The resected mass was measured 5.2 × 7.5 × 1.0 cm. Cut section revealed a well-defined keratinizing cystic mass. Histologic findings revealed a benign

cystic lesion lined by stratified squamous epithelium with a prominent granular cell layer. The cyst lumen is filled with the abundant keratin (Figure1). There was no evidence of malignancy. A final diagnosis of epidermoid cyst confirmed. The patient is under regular follow-up since last 10 months without any evidence of recurrence 10 months without any evidence of recurrence.

Discussion

Epidermal cysts are more common in men as in women [4-6]. Testicular epidermoid cyst is very rare. These benign lesions are about 3% of all testicular tumours [7]. The histopathologic features of testicular epidermoid cysts are similar with skin's epidermoid cysts [8]. Microscopically, epidermoid cysts revealed, a cystic lesion covered by stratified squamous epithelium with a prominent granular cell layer. The cyst lumen is filled with the abundant keratin, debris and desquamated cells [9]. Although the epithelial lining not to have malignant potential but malignant changes of basal cell carcinoma or squamous cell carcinoma from epidermal cysts have been reported [10]. Testicular sonographic findings in epidermal cysts described a sharply defined mass with a hyperechoic rim "onion ring" appearance of alternating hypoechogenicity layers of compacted keratin [8]. Magnetic resonance imaging (MRI) findings in these cysts revealed well-defined solid masses surrounded by a fibrous capsule [5]. This finding is similar to our case. Epidermoid cysts the prognosis is good. These cysts usually treated by conservative surgical excision and recurrence is uncommon [4].

Conclusion

Although testicular epidermal cysts are benign epithelial cysts and occurring of these lesions is very rare, malignant transformation has been reported in some cases. Therefore patient's follow-up is required.

References

1. Neville BW, Damm DD, Allen CM, Bouquot JE (2016) Oral and maxillofacial pathology. 4rd ed. Philadelphia: Saunder 357-370.
2. Kondo T, Kawahara T, Matsumoto (2016) Epidermal Cyst in the Scrotum Successfully Treated while Preserving the Testis: A Case Report. Case Rep Oncol 9(1): 235-240.
3. Dockerty M, Priestly JY (1942) Dermoid cysts of the testis. J Urol 48: 392-397.

-
4. Çakıroglu B, Sönmez N, Sinanoğlu O (2015) Testicular epidermoid cyst. Afr J Paediatr Surg 12(1): 89–90.
 5. Pattamaspong N, Muttarak M, Kitirattrakarn P (2014) Clinics in diagnostic imaging (149). Bilateral testicular epidermoid cysts. Georgian Med News 12(3): 14-7.
 6. Chen ST, Chiou HJ, Pan CC, Shen SH (2016) Epidermoid cyst of the testis: An atypical sonographic appearance. J Clin Ultrasound 44(7): 448-451.
 7. Bruni SG, Glanc P (2015) Bilateral Epidermoid Cysts of the Testes: A Characteristic Appearance on Ultrasonography. Ultrasound Q 31(3): 205-207.
 8. Lim J, Cho K (2015) Epidermoid cyst with unusual magnetic resonance characteristics and spinal extension. World J Surg Oncol 13: 240.
 9. Jeyaraj P, Sahoo NK (2015) An unusual case of a recurrent seborrhic/epidermal inclusion cyst of the maxillofacial region. J Maxillofac Oral Surg 14(1): 176–185.
 10. Prasad KK, Manjunath RD (2014) Multiple epidermal cysts of scrotum. Indian J Med Res 140: 318.