

Uncommon MRI and Echocardiographic Findings in a Patient of Carbon Monoxide Poisoning

Ashraf MU*, Anwar MR, Amir SH and Ashraf J

Department of Medicine, JN Medical College, AMU, Aligarh, Uttar Pradesh, P.O. Box: 202002, India

Abstract

Carbon Monoxide (CO) is a colorless and odorless gas which is nonirritating and is produced whenever there is incomplete combustion of any fossil fuel. There are diverse clinical effects of CO poisoning and they may be easily confused with other illnesses, such as nonspecific viral illness, benign headache, and various cardiovascular and neurologic conditions. Although initial neurologic manifestations may be subtle, but more profound exposure may produce altered mental status, confusion, syncope, seizure, acute stroke-like syndromes, and coma. Isolated seizures have been reported more often in pediatric patients. The cardiovascular effects of CO poisoning are manifested initially by tachycardia in response to hypoxia but more significant exposures may result in hypotension, arrhythmias, ischemia, infarction and even cardiac arrest. We present here an interesting case of one such patient who presented with features of severe myocardial depression and uncommon MRI findings secondary to carbon monoxide poisoning

Introduction

Carbon Monoxide (CO) is a colorless and odorless gas which is nonirritating and is produced whenever there is incomplete combustion of any fossil fuel. CO poisoning is the leading cause of poisoning mortality in the United States annually [1]. It is estimated that around 5000 to 6000 people die in the United States each year as a result of CO poisoning [2]. Patients who present with a history of suicide attempt with automobile exhaust may not represent a diagnostic dilemma but patients who present with symptoms of nausea and vomiting with headache that is improving can easily be misdiagnosed and discharged back to the dangerous environment where they may subsequently suffer more serious exposures later on.

There are diverse clinical effects of CO poisoning and they may be easily confused with other illnesses, such as nonspecific viral illness, benign headache, and various cardiovascular and neurologic conditions [3]. Initial symptoms after CO exposure include headache, nausea, and dizziness [4]. Although initial neurologic manifestations may be subtle, but more profound exposure may produce altered mental status, confusion, syncope, seizure, acute stroke-like syndromes, and coma. Isolated seizures have been reported more often in pediatric patients [5]. Abnormalities on neuroimaging studies involve lesions in globus pallidus [6]. Systemic hypotension in CO poisoning is correlated well with the severity of central nervous system structural involvement [7].

The cardiovascular effects of CO poisoning are manifested initially by tachycardia in response to hypoxia [8] but more significant exposures may result in hypotension, arrhythmias, ischemia, infarction and even cardiac arrest. Most cases of deaths after CO exposure have been reported to be due to cardiac arrhythmias [9]. Hypotension may also occur as a result of myocardial injury due to hypoxia/ischemia, direct myocardial depressant activity from myoglobin binding, peripheral vasodilatation [10] and may persist even after the resolution of neurologic and metabolic symptoms [11]. Experimental exposures to CO have resulted arrhythmias and decreased latency to the development of cardiac ischemia during stress testing [12]. CO exposure lowers the threshold for ventricular arrhythmias [13]. In healthy volunteers, without pre-existing cardiac lesions, CO exposure has shown to result in nonspecific ECG changes [14]. Myocardial infarction has also been reported in patients of CO poisoning in the absence of underlying coronary disease [15]. We present here a case of one such patient who presented with features of severe myocardial

depression and uncommon MRI findings secondary to carbon monoxide poisoning.

Case Report

A 25 year old male presented to us with a history of sudden onset loss of consciousness and respiratory distress. There was no preceding history of fever or any prior illness in the recent past. Patient had slept along with his colleagues in a closed room where they had lit fire as it was cold outside. The other three colleagues who had slept in the same room were also brought with a similar history, however they were declared brought dead. The patient had an unremarkable past medical history with no evidence of any chronic illness. There was no previous history of any abnormal movements, or head injury or probable ingestion of any toxic substance.

On examination the patient was a young male with average built and nutrition. His pulse rate was 110 per minute and the blood pressure was 70 mmHg. His respiratory rate was 46 per minute. There were bilateral crepitations in the chest. S1 and S2 were normal. Patient was unconscious with an EMV of 3/15. Pupils were dilated and there were no signs of meningeal irritation. Neck rigidity, Kernig's sign and Brudzinski's sign were negative.

The patient was immediately intubated and was put on mechanical ventilation. Based on the history and the preceding surroundings, a suspicion of Carbon Monoxide poisoning was made. Patient's blood was drawn to see its colour and it was found that his blood was cherry-red in colour. Patient's total Leucocyte count was 18400/mm³, Differential Leucocyte Count was P86L14. Electrocardiogram (EKG) was normal and liver function tests were normal. His blood Urea was 54

***Corresponding author:** Muhammad Uwais Ashraf, Department of Medicine, JN Medical College, AMU, Aligarh, Uttar Pradesh, P.O. Box: 202002, India, Tel: 09760159391; E-mail: uwaisashraf@gmail.com

Received January 01, 2015; **Accepted** July 22, 2015; **Published** July 25, 2015

Citation: Ashraf MU, Anwar MR, Amir SH, Ashraf J (2015) Uncommon MRI and Echocardiographic Findings in a Patient of Carbon Monoxide Poisoning. J Neurol Disord 3: 242. doi:10.4172/2329-6895.1000242

Copyright: © 2015 Ashraf MU, et al. This is an open-access article distributed under the terms of the Creative Commons Attribution License, which permits unrestricted use, distribution, and reproduction in any medium, provided the original author and source are credited.

mg% and Serum Creatinine was 1.4 mg%. Arterial Blood Gas (ABG) analysis revealed a pH of 7.29, pCO₂ of 38 mmHg pO₂ of 78 mmHg and bicarbonate level of 18.3 mmol/l. Carboxyhemoglobin levels were sent which came out to be 60%.

The patient was put on Ventilatory Support and the ventilator settings were adjusted to deliver an FiO₂ (Fraction of Inspired Oxygen) of 100%. Intravenous Broad spectrum antibiotics and dexamethasone were started. Patient was also given intravenous multivitamins. Vasopressors were started soon after resuscitation. However, the patient's shock did not improve even after one day of vasopressor support. On second day, the EKG revealed an ST-elevation with concavity upwards in the inferior leads (Figure 1). Cardiac troponins were done which revealed a level of 2.34 ng/ml. A suspicion of myocarditis was made and an echocardiography was done which revealed global hypokinesia with severe left ventricular systolic dysfunction and an ejection fraction of 35%.

Treatment was continued with intravenous antibiotics, mechanical ventilation with high FiO₂ and supportive measures. The patient improved after four days of aggressive ICU management. At the time of extubation the patient was irritable and his carboxyhemoglobin levels were 12%. An MRI of the brain was ordered which revealed altered signal intensity lesions involving globus pallidus of bilateral basal ganglia and left mesial temporal lobe showing restricted diffusion (Figure 2).

After another day of further supportive care, the patient became fully conscious with an EMV of 15/15. The state of shock improved and vasopressors were weaned off. EKG changes reverted to normal. Cardiac troponin was repeated which showed a decreased level of 1.02 ng/ml. Patient was discharged in a stable condition and he came for follow up after a week and he was found to be symptom free. EKG was normal and a repeat echocardiography was done which revealed improved cardiac functions with an ejection fraction of 58% (Figure 3). We are following the patient for chronic sequelae.

Discussion

Carbon Monoxide (CO) is a ubiquitous contaminant of atmosphere that requires prevention and control measures to ensure adequate protection of public health. The presence of carbon monoxide in the environment is usually not appreciated by an exposed person because it is colorless, tasteless, odorless, and nonirritating. It is readily absorbed from the lungs into the blood and it forms a tight complex with hemoglobin (Hb) known as carboxyhemoglobin (COHb). The presence of COHb in the blood decreases the oxygen carrying capacity, and reduces the availability of oxygen to body tissues thus resulting in tissue hypoxia.

CT of the brain in patients with severe CO poisoning may show certain signs which are mostly due to hypoxia, ischemia, and hypotension. However, a well-documented CT finding in CO exposure is low density lesions in bilateral globus pallidus [16]. The reason for development of this lesion has been linked to decrease in local low blood flow to the globus pallidus [17], metabolic acidosis, and hypotension in animal models. Globus pallidus lesions may be delayed for several days after presentation and may resolve gradually [18]. Sometimes associated white matter lesions may also be present [16].

MRI in patients of CO poisoning may show diffuse, symmetric white matter lesions, mainly in the periventricular areas. The centrum semiovale, deep subcortical white matter, thalamus, basal ganglia, and hippocampus may also be involved [19]. Overall outcomes are

poorer in patients who have abnormal neuroimaging findings after CO exposure and are more likely to go on to develop persistent functional neurologic impairment [20]. SPECT scanning correlates well with the development of delayed neurologic sequelae [21].

Carbon monoxide has a much higher affinity for hemoglobin than oxygen, and thus it attaches to the hemoglobin and impairs the oxygen carrying capacity. As a result, CO poisoning leads to reduced oxygen delivery to the tissues. Cardiac toxicity has been reported to occur as a result of myocardial hypoxia or a direct toxic effect of CO on myocardial mitochondria. Cardiac involvement may occur soon after exposure, or it may take several days to manifest. Sinus tachycardia and various arrhythmias, including ventricular extrasystoles and atrial fibrillation may occur even in the absence of myocardial damage [22]. Angina pectoris may occur even in patients without pre-existing CAD [23].

Myocardial infarction has been reported earlier in patients with underlying CAD [24] as well as those without preexisting CAD [25]. CO poisoning causes myocardial infarction by severe generalized tissue hypoxia and by toxic effects on the myocardial mitochondria [26]. Other factors which have been implicated are inadequate myocardial perfusion and increased thrombotic tendency leading to myocardial oxygenation [26]. ST-segment and T wave abnormalities are common and transient ventricular dysfunction may occur. Administration of 100% oxygen usually results in rapid recovery.

Our case demonstrates that aggressive ICU management with regular delivery of higher FiO₂ may revert both myocardial as well as neurological complications of CO poisoning.

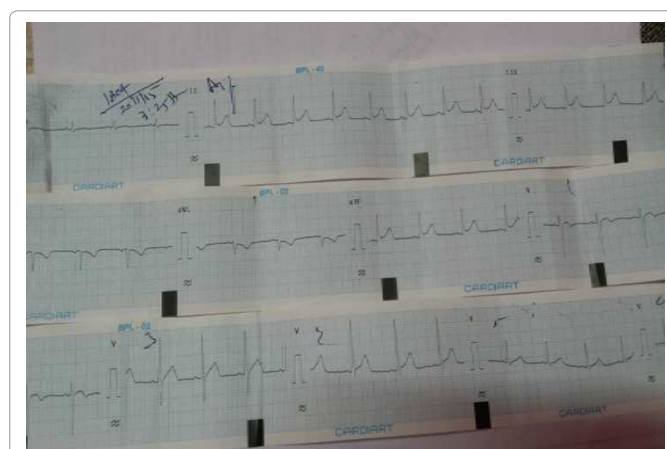


Figure 1: Graph of echocardiography.

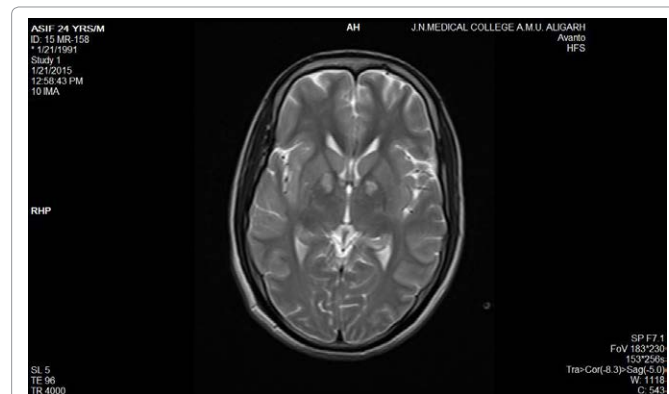

Figure 2: MRI of the brain.

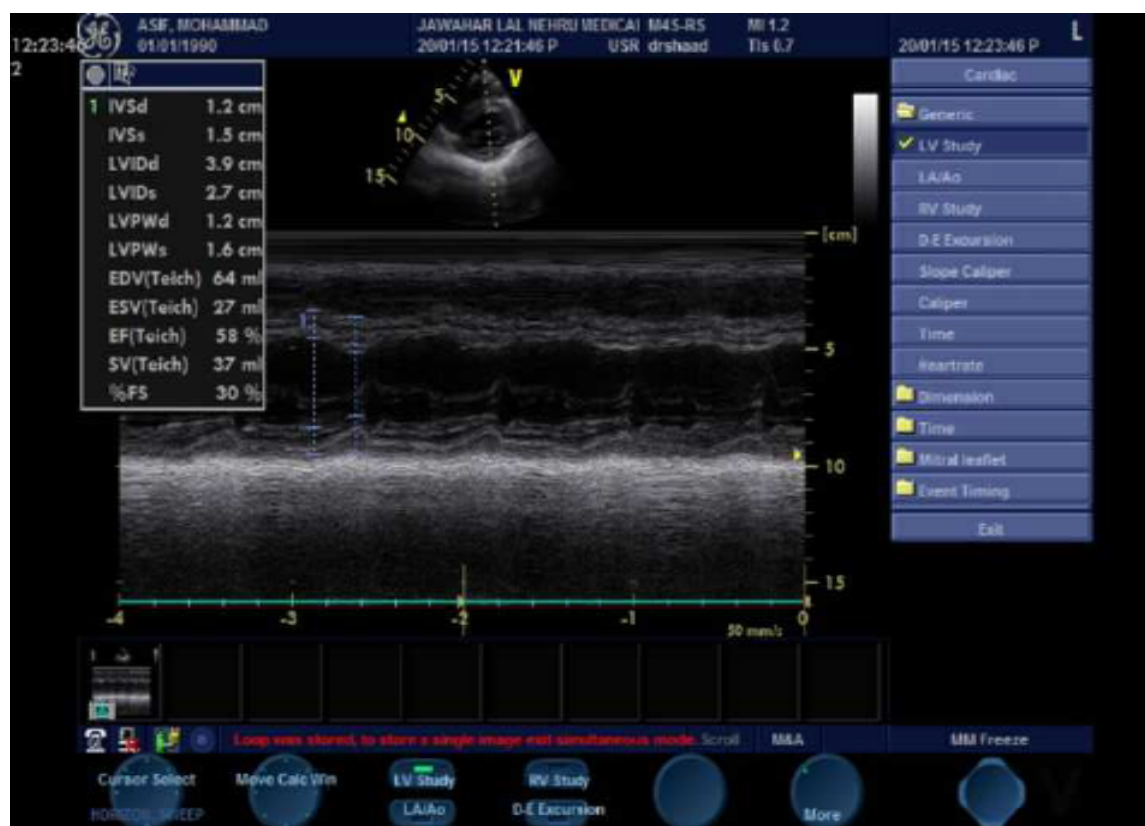

Figure 3: Results of Echocardiography.

Conclusion

Carbon monoxide leads to a large number of accidental poisonings and deaths reported throughout each year. Myocardial injury is a common feature of CO poisoning and these patients are at an increased risk of mortality. Patients of suspected exposure to CO should always be screened for myocardial injury. The emphasis should be on delivery of high FiO₂ to the patient even if hyperbaric oxygen therapy is not available. There is no specific treatment of the complications other than supportive care and 100% oxygen which reduces the half-life of COHb and minimizes complications.

References

1. Tomaszewski C (2002) Carbon monoxide. In: Goldfrank's toxicologic emergencies. (7th edn), McGraw-Hill, New York.
2. Stewart RD, Peterson JE, Baretta ED, Bachand RT, Hosko MJ, et al. (1970) Experimental human exposure to carbon monoxide. Arch Environ Health 21: 154-164.
3. Baker MD, Henretig FM, Ludwig S (1988) Carboxyhemoglobin levels in children with nonspecific flu-like symptoms. J Pediatr 113: 501-504.
4. Stewart RD, Peterson JE, Baretta ED, Bachand RT, Hosko MJ, et al. (1970) Experimental human exposure to carbon monoxide. Arch Environ Health 21: 154-164.
5. Herman LY (1998) Carbon monoxide poisoning presenting as an isolated seizure. J Emerg Med 16: 429-432.
6. Silver DA, Cross M, Fox B, Paxton RM (1996) Computed tomography of the brain in acute carbon monoxide poisoning. Clin Radiol 51: 480-483.
7. Song SY, Okeda R, Funata N, Higashino F (1983) An experimental study of the pathogenesis of the selective lesion of the globus pallidus in acute carbon monoxide poisoning in cats. With special reference to the chronologic change in the cerebral local blood flow. Acta Neuropathol 61: 232-238.
8. Penney DG (1988) Hemodynamic response to carbon monoxide. Environ Health Perspect 77: 121-130.
9. Hardy KR, Thom SR (1994) Pathophysiology and treatment of carbon monoxide poisoning. J Toxicol Clin Toxicol 32: 613-629.
10. Penney DG (1990) Acute carbon monoxide poisoning: animal models: a review. Toxicology 62: 123-160.
11. Yanir Y, Shupak A, Abramovich A (2002) Cardiogenic shock complicating acute carbon monoxide poisoning despite neurologic and metabolic recovery. Ann Emerg Med.
12. DeBias DA, Banerjee CM, Birkhead NC, Greene CH, Scott SD, et al. (1976) Effects of carbon monoxide inhalation on ventricular fibrillation. Arch Environ Health 31: 42-46.
13. Stewart RD, Peterson JE, Fisher TN, Hosko MJ, Baretta ED, et al. (1973) Experimental human exposure to high concentrations of carbon monoxide. Arch Environ Health 26: 1-7.
14. Marius-Nunez AL (1990) Myocardial infarction with normal coronary arteries after acute exposure to carbon monoxide. Chest 97: 491-494.
15. Miura T, Mitomo M, Kawai R, Harada K (1985) CT of the brain in acute carbon monoxide intoxication: characteristic features and prognosis. AJNR Am J Neuroradiol 6: 739-742.
16. Song SY, Okeda R, Funata N, Higashino F (1983) An experimental study of the pathogenesis of the selective lesion of the globus pallidus in acute carbon monoxide poisoning in cats. With special reference to the chronologic change in the cerebral local blood flow. Acta Neuropathol 61: 232-238.
17. Vieregge P, Klostermann W, Blümm RG, Borgis KJ (1989) Carbon monoxide poisoning: clinical, neurophysiological, and brain imaging observations in acute disease and follow-up. J Neurol 236: 478-481.

18. Zagami AS, Lethlean AK, Mellick R (1993) Delayed neurological deterioration following carbon monoxide poisoning: MRI findings. J Neurol 240: 113-116.
19. Parkinson RB, Hopkins RO, Cleavinger HB, Weaver LK, Victoroff J, et al. (2002) White matter hyperintensities and neuropsychological outcome following carbon monoxide poisoning. Neurology 58: 1525-1532.
20. Pavese N, Napolitano A, De Iaco G, Canapicchi R, Collavoli PL, et al. (1999) Clinical outcome and magnetic resonance imaging of carbon monoxide intoxication. A long-term follow-up study. Ital J Neurol Sci 20: 171-178.
21. Aslan S, Erol MK, Karcioglu O, Meral M, Cakir Z, et al. (2005) The investigation of ischemic myocardial damage in patients with carbon monoxide poisoning. Anadolu Kardiyol Derg 5: 189-193.
22. Allred EN, Bleecker ER, Chaitman BR, Dahms TE, Cottlieb SO, et al. (1991) Effects of carbon monoxide on myocardial ischemia. Environ Health Perspect.
23. Fiorista F, Casazza F, Comolatti G (1993) Silent myocardial infarction caused by acute carbon monoxide poisoning. G Ital Cardiol 23: 583-587.
24. Marius-Nunez AL (1990) Myocardial infarction with normal coronary arteries after acute exposure to carbon monoxide. Chest 97: 491-494.
25. Lange RA, Hillis LA (2005) Toxins and the heart. In: Heart Disease: A Textbook of Cardiovascular Medicine, (7th edn) Elsevier Saunders, Philadelphia.
26. Mokaddem A, Sdiri W, Selmi K, Darghouth B, Mahjoub H, et al. (2004) A rare cause of myocardial infarction: carbon monoxide intoxication. Tunis Med 82: 320-323.

Citation: Ashraf MU, Anwar MR, Amir SH, Ashraf J (2015) Uncommon MRI and Echocardiographic Findings in a Patient of Carbon Monoxide Poisoning. J Neurol Disord 3: 242. doi:[10.4172/2329-6895.1000242](https://doi.org/10.4172/2329-6895.1000242)

Submit your next manuscript and get advantages of OMICS Group submissions

Unique features:

- User friendly/feasible website-translation of your paper to 50 world's leading languages
- Audio Version of published paper
- Digital articles to share and explore

Special features:

- 400 Open Access Journals
- 30,000 editorial team
- 21 days rapid scholarly review process
- Quality, quick editorial, peer review and publication processing
- Indexing at PubMed (partial), Scopus, EBSCO, Index Copernicus and Google Scholar etc
- Sharing Option: Social Networking Enabled
- Authors, Reviewers and Editors rewarded with online Scientific Credits
- Better discount for your subsequent articles

Submit your manuscript at: <http://scholarscentral.com/>