

The Youngest Paediatric Presentation of IgA Nephropathy

Kibriya Fidan*, Neil J Sebire and Stephen D Marks

Department of Pediatric Nephrology, Gazi University, Besevler, Ankara, Turkey

*Corresponding author: Kibriya Fidan, MD, Faculty of Medicine, Department of Pediatric Nephrology, Gazi University, 06500, Besevler, Ankara, Turkey, Tel: +90 312 2025126; Fax: +903122029006; E-mail: kibriyafidan@yahoo.co.uk

Received Date: October 08, 2017; Accepted Date: November 02, 2017; Published Date: November 11, 2017

Copyright: © 2017 Fidan K, et al. This is an open-access article distributed under the terms of the Creative Commons Attribution License, which permits unrestricted use, distribution, and reproduction in any medium, provided the original author and source are credited.

Abstract

Objectives: To describe the clinical course and three year follow-up of the youngest case of IgA nephropathy (IgAN).

Method: Retrospective case note review.

Result: A 26 month old girl presented with after intermittent macroscopic haematuria, nephrotic syndrome without hypertension or renal dysfunction. She had 3+ proteinuria and 3+ of haematuria on urinary dipstick testing. Her urine showed $>500 \times 10^6/L$ red without white cells or growth on culture and albumin: creatinine ratio of 253 mg/mmol without hypercalciuria. She was hypoalbuminaemic at 25 g/L. Her ASO titre and complements were normal with elevated IgA of 1.57 g/L. Her renal biopsy demonstrated IgA nephropathy (IgAN) with diffuse global mesangial proliferative glomerulonephritis with associated diffuse strong granular mesangial IgA deposition. She was commenced on an ACEI together with fish-oil supplements. She had evidence of hyperfiltration without proteinuria, macroscopic haematuria or hypertension at follow-up of three years.

Conclusion: This is the youngest published case of IgA nephropathy. Detecting IgA nephropathy early may offer the possibility of treatment to prevent progression of the disease.

Keywords IgA nephropathy; Paediatric; Proliferative glomerulonephritis

Introduction

IgA nephropathy is the most common form of glomerulonephritis identified in paediatric renal biopsies of children. Up to 40% of percutaneous renal biopsies are performed in children due to macroscopic haematuria and/or proteinuria.

The prevalence of IgAN may be underestimated as the disease may present with adult-onset end stage renal failure (ESRF) without previous childhood history. Eighteen percent of patients show progression of renal disease within ten years after the first renal biopsy and long-term outcome studies predict that 10-20% of adult patients will develop ESRF within ten years [1].

Detecting IgAN early in its natural history may offer the possibility of treatment to prevent progression of renal failure. There is controversial evidence regarding the efficacy of treatment in IgAN with some randomised controlled trials supporting the beneficial effect of either prednisolone or fish-oil supplements in regards to decreasing proteinuria and slowing the progression of renal impairment [2]. The clinical decision to treat a patient who has IgAN with angiotensin converting enzyme inhibitors (ACEI) alone or to add immunosuppressive or other agents, largely depends on the presence of ongoing disease activity with proteinuria (which can also represent damage from previously active disease).

A recent, multi-centre placebo-controlled trial in children and young adults reported equal efficacy of prednisolone, and fish-oil supplements in significantly reducing proteinuria compared to

controls. Long-term follow-up of adults with IgAN appears to indicate the greatest benefit is achieved if treatment is started early in the course of the disease.

We present the case of a young child presenting with IgAN who made a good response to therapy with follow-up of three years.

Case Presentation

A 26-month old girl presented with macroscopic haematuria, nephrotic syndrome without hypertension or renal dysfunction. She developed subsequent intermittent macroscopic haematuria for two months. She had no precipitating viral upper respiratory tract infection. She had mild peri-umbilical abdominal pain, not associated with loin pain. She had normal antenatal, postnatal history without past medical or family history of note with normal growth and development.

On examination, she was well, with weight-height above the 50th centile, and normal blood pressure of 84/52 mmHg. She had only mild periorbital swelling.

She had 3+ proteinuria and 3+ of haematuria on urinary dipstick testing with >500 red blood cells $\times 10^6/L$ without white cells on urine microscopy. Her urine albumin:creatinine ratio was elevated at 253 mg/mmol without evidence of hypercalciuria. She had β -haemolytic streptococcus group G growing from her throat swab.

She had a normal full blood count with haemoglobin of 14 g/dL and normal coagulation screen. She had an elevated ESR of 57 mm/hour. She had normal serum electrolytes with a plasma creatinine of 29 $\mu\text{mol/L}$ but was hypoalbuminaemic at 25 g/L. She had a normal ASO-

titre of 104 IU/ml and a normal anti-DNAase-B of <100 µ/ml. She had normal complements C3 and C4 (1.32 g/L and 0.17 g/L respectively) with negative ANA, normal IgG of 11.8 g/L, IgM 1.0 g/L although elevated IgA at 1.9 g/L (normal 0.3-1.3 g/L).

She had normal renal ultrasound without evidence of renal calculi. She had evidence of hyperfiltration injury with an increased formal51-Cr-EDTA glomerular filtration rate of 165 ml/min/1.73m².

Her renal biopsy demonstrated IgAN with a diffuse mesangial proliferative glomerulonephritis and two of 29 glomeruli showing superimposed small segmental scars indicating previous focal segmental activity (Figures 1A and 1B). Immunohistochemical staining revealed strong diffuse granular mesangial IgA deposition with weaker IgM deposition but no deposition of IgG, C1q or C3 (Figure 1C). Electron microscopic examination demonstrated numerous mesangial and paramesangial electron dense deposits with scattered capillary loop deposits present in occasional areas (Figure 1D).

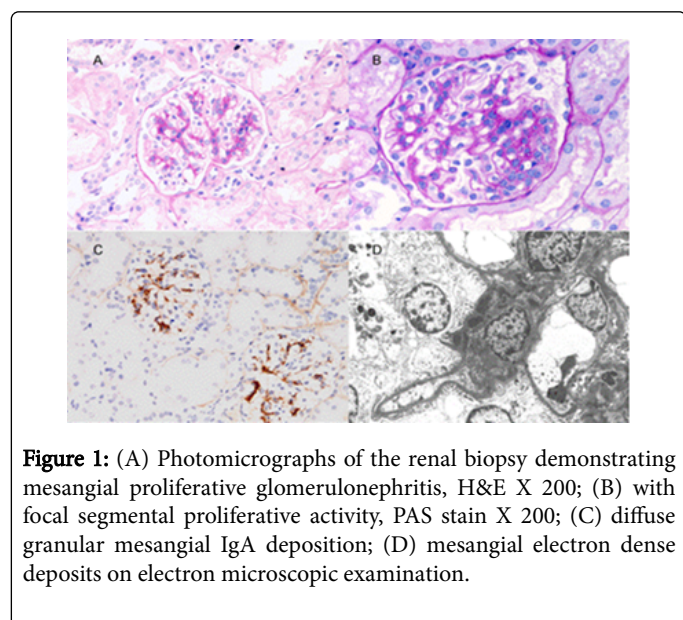


Figure 1: (A) Photomicrographs of the renal biopsy demonstrating mesangial proliferative glomerulonephritis, H&E X 200; (B) with focal segmental proliferative activity, PAS stain X 200; (C) diffuse granular mesangial IgA deposition; (D) mesangial electron dense deposits on electron microscopic examination.

She was commenced on an ACEI together with fish-oil supplements and had a further episode of macroscopic haematuria at six months after presentation lasting two days associated with a febrile viral upper respiratory tract infection. At follow-up of three years, her proteinuria has decreased from 2+ to 1+ although she continues to have 2+ or 3+ intermittent microscopic haematuria. She has a normal urine albumin to creatinine ratio so her ACEI and fish-oil supplements have been discontinued. Her serum albumin has increased from 25 g/L to 44 g/L with a repeat formal glomerular filtration rate of 160 ml/min/1.73m².

Discussion

Our case report of a 26 month old with IgAN is the youngest age to present in the literature, with the previous youngest age reported as 30 months old (Table 1) [3].

In many cases it is not known when IgAN starts to inflict glomerular injury, but recent studies that have shown genetically determined abnormalities in glycosylation of the IgA molecule suggest that this may begin in early life. Early descriptions of childhood IgAN suggested that it was a relatively benign condition. The clinical course

is variable with many patients developing slowly progressive renal disease. The age at onset and presence of tubulointerstitial lesions are the strongest predictors of a progressive course of childhood IgAN.

Reference	No. of patients (n)	Sex (M)	Study type	Mean age (years)	Minimum age (years)	Maximum age (years)
2	31	19	Retrospective	13.8	7.1	17.7
6	1	1	Case report	5.0	-	-
4	40	17	Prospective	11.4	4.4	15.4
7	99	63	Retrospective	12.2	4	17
5	19	11	Retrospective	12.0	4.1	17.7
3	500	279	Retrospective	10.9	2.5	19.6

Table 1: Patient demographics in published IgAN studies.

IgAN is an immune-complex-mediated glomerulonephritis defined immunohistologically by the presence of glomerular IgA deposits accompanied by a variety of histopathological lesions. The presence of glomerulosclerosis, crescents, interstitial fibrosis or tubular atrophy provide the most reliable histological indicators of poor outcome. The percutaneous renal biopsy of our patient confirmed IgAN with a mesangial proliferative glomerulonephritis and mesangial deposition of IgA. A variety of histological parameters and classifications have been used to attempt to predict prognosis in patients with IgAN. The International IgAN Network, working with members of the Renal Pathology Society, has established an international working group which is developing a consensus classification. Reports from different regions of the world indicate differences in the pattern of disease class. Mesangial proliferation (subclass I and II) was predominant in a report from Macedonia where proliferative and crescentic forms were responsible for up to 30% of reported IgAN. As expected, the severity of renal histology, usually defined by focal sclerotic lesions or crescents, is associated with poor outcome for paediatric IgAN. Recent prospective studies showed that 40% of patients with as little as 10% cellular crescent will progress to ESRF [1,3,4].

IgAN and Henoch-Schönlein purpura nephritis (HSN) are histologically indistinct diagnoses and represent the most commonly occurring form of paediatric glomerulonephritis. The clinical, genetic and immunologic features of these two conditions are so closely linked that one could consider HSN as the systemic form of IgAN. IgAN seems to be a renal-restricted form of HSN. In the majority of cases, IgAN is an isolated renal disease without systemic manifestations. Approximately 40-50% of patients present with recurrent macroscopic haematuria, which usually coincides with mucosal infections or exercise. Asymptomatic macroscopic haematuria with or without proteinuria is the presentation in 30-50% of most series. However, IgAN and minimal change disease have previously been reported as co-existing together in children. Our case also presented with nephrotic syndrome and recurrent macroscopic haematuria but her biopsy demonstrated IgAN with mesangial IgA deposits, confirmed

with electron-dense deposits in the same distribution on electron microscopy [5-7].

Previous reports have suggested that the outcome of childhood IgAN is age related. There was a peak in poor outcomes among patients diagnosed after the age 16 years [1,2].

Conclusion

Morbidity is high after childhood IgAN. The prognosis is predictive from age at presentation, presentation of chronic changes in the renal biopsy together with the presence of proteinuria at the onset. Our patient is the youngest case of IgA nephropathy reported in the literature. She has evidence of hyperfiltration without proteinuria, macroscopic haematuria or hypertension at follow-up of three years.

Acknowledgement

The project was supported by the National Institute for Health Research, Biomedical Research Centre at Great Ormond Street Hospital for Children NHS Foundation Trust and University College London. (R&D NO. 10NU13)

Consent

Written informed consent was obtained from the patient's parent for publication of this case report and any accompanying images. A copy

of the written consent is available for review by the Editor-in-Chief of this journal.

References

1. Tumblin JA, Madaio MP, Hennigar R (2017) Idiopathic IgA nephropathy: pathogenesis, histopathology and therapeutic options. Clin J Am Soc Nephrol 2: 1054-1061.
2. Ronkainen J, Ala-Houhala M, Autio-Harminen H (2006) Long-term outcome 19 years after childhood IgA nephritis: a retrospective cohort study. Pediatr Nephrol 21: 1266-1273.
3. Yata N, Nakanishi K, Shima Y (2008) Improved renal survival in Japanese children with IgA nephropathy. Pediatr Nephrol 23: 905-912.
4. Haas M (1997) Histologic subclassification of IgA nephropathy: A clinicopathologic study of 244 cases. Am J Kidney Dis 29: 829-842.
5. Edström Halling S, Söderberg MP, Berg UB (2009) Treatment of severe Henoch-Schönlein and immunoglobulin A nephritis. A single center experience. Pediatr Nephrol 24: 91-97.
6. Tasic V, Korneti P, Ristoska-Bojkovska N (2003) Idiopathic hypercalciuria preceding IgA nephritis in a child with recurrent hematuria. Pediatr Nephrol 18: 394-396.
7. Haas M, Rahman MH, Cohn RA (2008) IgA nephropathy in children and adults: comparison of histologic features and clinical outcomes. Nephrol Dial Transplant 23: 2537-2545.