

# Sacrocolpopexy (SCP) - A Cohort Study Looking at Short, Medium and Long Term Outcome

Veenu Tyagi<sup>1\*</sup>, Robert Hawthorn<sup>2</sup> and Karen Guerrero<sup>3</sup>

<sup>1</sup>Subspeciality Trainee Urogynaecology, NHS Greater Glasgow and Clyde, Southern General Hospital, 1345 Govan Road, Glasgow, G51 4TF, USA

<sup>2</sup>Consultant Obstetrics and Gynaecology, NHS Greater Glasgow and Clyde, Southern General Hospital, 1345 Govan Road, Glasgow, G51 4TF, USA

<sup>3</sup>Consultant Subspecialist Urogynaecologist, NHS Greater Glasgow and Clyde, Southern General Hospital, 1345 Govan Road, Glasgow, G51 4TF, USA

## Abstract

In this study we evaluate the outcome, complications and need for repeat surgery after Sacrocolpopexy (SCP) over the last 10 years. 49 (66%) case notes were reviewed. 28 (57%) patients SCP. The remainder had concomitant pelvic floor and / or incontinence procedures.

12 patients had laparoscopic SCP and 37 were performed by open technique. 8(16%) patients' required further surgery either for new prolapse or recurrent prolapse.

The short term success with sacrocolpopexy was high (97.9%) with the rate being maintained with medium term (100%) and long term (91.66%) follow up. Rates of complication, especially mesh exposure, was very low in our study. This suggests maintaining the integrity of vaginal vault during SCP might be a key factor in reducing the incidence of mesh exposure with SCP.

However large numbers in long term follow up is needed to make any definite conclusion. Sacrocolpopexy (SCP) - A cohort study looking at short, medium and long term outcome.

**Keywords:** Sacrocolpopexy; Laparoscopy; Urogynaecology

## Background

Numerous surgical approaches have been described to treat apical Pelvic Organ Prolapse (POP) but only a few have been subjected to vigorous assessment for their anatomical and functional outcome. Abdominal Sacrocolpopexy (ASCP) proposed by Lane in 1962 has been most widely studied and been shown to be reliable and durable [1]. Sacrocolpopexy (SCP) for apical vaginal prolapse is a safe and efficacious procedure. Success rates of over 78-100% have been reported [1-4].

The laparoscopic route potentially combines the success rate of an abdominal approach with the faster recovery time associated with minimally invasive technique [4]. A recent RCT comparing the two approaches for treating post hysterectomy vault prolapse concluded that laparoscopic sacrocolpopexy with mesh is equivalent to open sacrocolpopexy with regards to vaginal vault correction. Furthermore hospital stay, perioperative and post operative morbidity, and quality of life indices appear similar in the two groups [5].

We performed a retrospective review to look at the short term, medium term and long term outcome of SCP in our unit.

## Aims of Study

Primary outcome was to assess success at short term (<6 months), medium term (6 months - 5 years) and long term (>5 years).

Secondary Outcomes included complications and the need for repeat prolapse surgery.

## Methods

The study was performed in a tertiary urogynaecology referral centre. Women who had undergone a SCP between 2002 -2011 were identified by computer coded procedure logs.

The health board operates an electronic health record system allowing identification of any treatment patients may have received within it, at any of its hospitals or medical specialties. This allowed

identification of re-presentations/problems that may have presented elsewhere in the region.

Hospital records, letters and operative notes were reviewed to obtain data including demographics, pelvic examination findings, gynaecological procedure performed in addition to SCP, intra operative and postoperative complications.

## Procedure

Standard surgical procedure was followed in all these patients for both open and closed SCP. All patients had Examination under Anaesthesia (EUA) to assess POP and establish where support (and mesh anchorage) was required.

In LSCP mesh was attached to the posterior vaginal wall after vaginal dissection. Vaginal vault peritoneum was opened and the mesh inserted into the abdomen for laparoscopic retrieval and anchoring. Open SCP were performed with a standard transverse incision and vaginal skin was not opened. In both routes mesh was sutured on the sacral promontory using permanent sutures like ethibond or prolene or laparoscopic tacs.

On the vagina delayed absorbable sutures were used. Position of sutures on the vaginal wall varied depending on the EUA findings and associated anterior and/+ or posterior vaginal wall prolapse. Over the study period these techniques remained unchanged. The type of mesh changed as more recently lighter meshes and Y grafts were introduced.

**\*Corresponding author:** Veenu Tyagi, Subspeciality trainee urogynaecology, NHS Greater Glasgow and Clyde, Southern General Hospital, 1345 Govan Road, Glasgow, G51 4TF, USA, Tel: 0044 141 2012237; E-mail: [veenuTyagi@yahoo.com](mailto:veenuTyagi@yahoo.com)

**Received** September 27, 2013; **Accepted** November 25, 2013; **Published** November 29, 2013

**Citation:** Tyagi V, Hawthorn R, Guerrero K (2013) Sacrocolpopexy (SCP) - A Cohort Study Looking at Short, Medium and Long Term Outcome. Med Surg Urol 2: 118. doi:[10.4172/2168-9857.1000118](https://doi.org/10.4172/2168-9857.1000118)

**Copyright:** © 2013 Tyagi V, et al. This is an open-access article distributed under the terms of the Creative Commons Attribution License, which permits unrestricted use, distribution, and reproduction in any medium, provided the original author and source are credited.

As newer laparoscopic tools were introduced, these facilitated the LSCP but technique remained unaltered.

## Results

85 potential patients were identified (Figure 1). We obtained 60 patients (70%) case notes. 10 case notes were destroyed as they had not attended any hospital within the health board for over 5 years. Remaining case notes could not be located. Of the 60 case notes reviewed, 11 had not actually undergone SCP. Therefore we reviewed 49/74 (66%) of our potential cohort of patients (assuming all the remaining patients we were unable to review case notes underwent a SCP).

The median age distribution of patients in our cohort is 59 (range 27-84) with 34 (69%) patients being more than 50 years old at the time of surgery.

All except one woman were parous. Most (42-86%) were postmenopausal.

10 women (20%) were sexually active and 5 women (10%) were

not. The remainder (70%) did not have this information recorded in their notes.

25 (51%) patients had previous surgery for Pelvic Organ Prolapse (POP). Of these 9 (36%) had surgery for vault prolapse, either intravaginal sling or sacrospinous fixation (Table 1). None had had a previous SCP.

Pre-operatively, 20 (41%) patients had single compartment apical (vault/cervical) prolapse. 5 (25%) of them had total vaginal eversion. Remaining patients 29 (59%) had associated anterior and/or posterior compartment prolapse.

All patients had stage 2 or higher POP (POPQ or Baden Walker classification), with 11 (22.4%) patients having stage 4 prolapse.

12 (25%) patients had Laparoscopic SCP (LSCP) and 37 (75%) were performed by open technique (OSCP).

28(57%) patients had only SCP as the sole procedure to address POP, 14 (50%) having a concomitant Sub-total Hysterectomy (STH). 5 women had SCP with STH and an incontinence procedure. Thirteen women (26%) underwent a concomitant anterior or posterior compartment repair, 4 of which also had incontinence procedure. 3 women (6%) had a SCP with a rectopexy.

## Primary Outcome

### Success rates

Short term outcome of SCP both laparoscopic and open was defined as  $\leq$  stage 1 apical prolapse on clinical examination (objective) and/ or need for repeat surgery for prolapse. For medium and long term outcome success was defined as patient need for further surgery or representation with POP.

The short term outcome with sacrocolpopexy for repair of vaginal vault prolapse was high (97.9%) with the rate being maintained with medium term (97.5%) and long term (91.66%) follow up (Table 2).

The median duration of hospital stay of all patients was 3 days (range 2-6 days). In our cohort, patients who had LSCP went home a day sooner (median day 2, range 2-6) as compared to those who had OSCP (median day 3, range 2-6).

## Secondary Outcomes

### Intra-operative complications

2 (4%) patients sustained a bladder injury during LSCP. These were repaired laparoscopically with the SCP procedure completed. Bladder injuries subsequently healed without any long term problems. There were no intra operative complications documented in the OSCP group.

### Postoperative complications

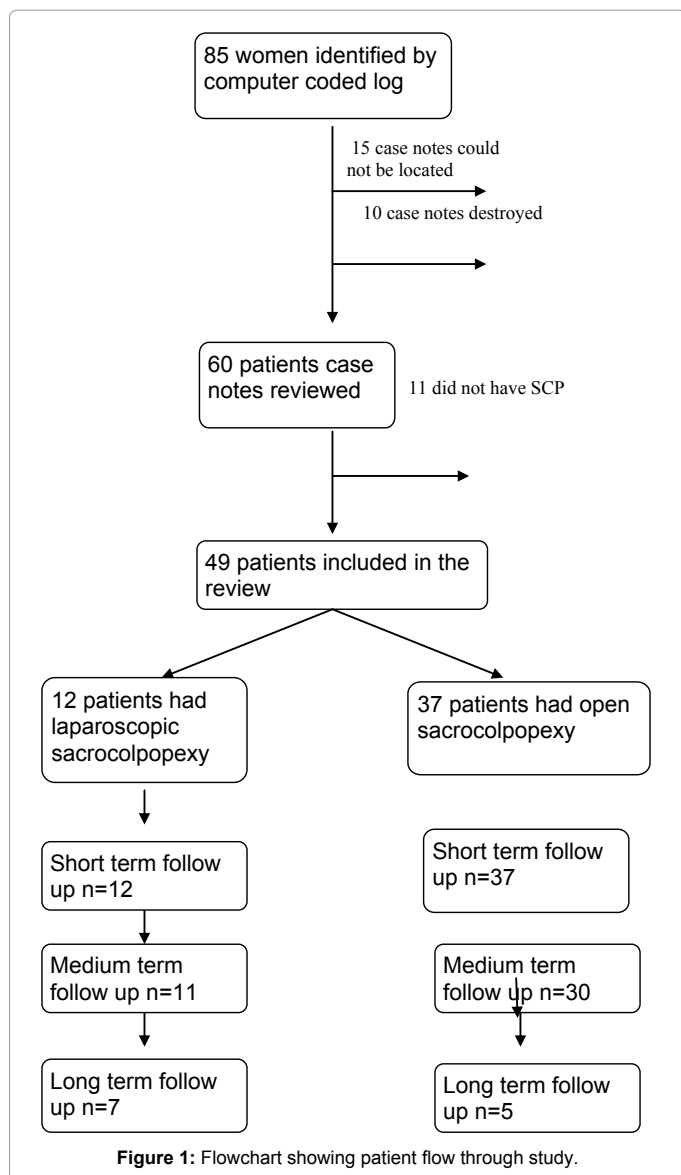
**Short term:** Laparoscopic - SCP (n=12)

1 patient had voiding dysfunction (8%) which persisted at medium term follow up. She was found to have high residuals with stage 1-2 cystocele and was taught Intermittent Self Catheterisation (ISC). The Cystocele progressed to stage 3 at which point she had anterior colporrhaphy and the voiding dysfunction resolved.

There was 1 case of omental herniation through port site on 7<sup>th</sup> postoperative day which was dealt with laparoscopically.

**Open - SCP (n=37)**

2 patients were documented to have Urinary Tract Infections



Type of surgery	Number of patients (n=49)	
Total Abdominal Hysterectomy	8(24%)	
Apical POP repair	9(27%)	
Vaginal Pelvic Floor Repair	Isolated compartment	7(21%)
	PFR+vaginal hysterectomy	6(18%)
	Incontinence procedures	3(9%)
No previous surgery	16 (33%)	

**Table 1:** Previous Gynaecological Surgery.

Overall success rate	Short term	Medium term	Long term
	48/ 49 (97.9%)	40/41 (97.5%)	11/12 (91.66%)
LSCP	11/12 (92%)	11/11 (100%)	7/7 (100%)
OSCP	37/37 (100%)	29/30 (97%)	4/5 (80%)

**Table 2:** Success for apical prolapse repair with SCP in short, medium and long term.

postoperatively requiring oral antibiotics. There were 2 cases of wound infection, which were managed with intravenous followed by oral antibiotic, and 1 case of wound gaping which was sutured under local anaesthetic.

3 patients had voiding dysfunction (8%). Of this, 1 patient required ISC which resolved by week 3 and was discharged. 1 underwent cystoscopy and urethral dilatation and voiding dysfunction subsequently improved and was discharged. Both of the above patients did not have any concomitant incontinence or pelvic floor repair procedure. One patient had concomitant TVTO at the time of SCP which was released 16 months later.

**Medium term:** LSCP (n=11) There were 2 (18%) cases of de novo detrusor overactivity and one case of stress urinary incontinence (9%) which were all managed conservatively.

OSCP (n=30)

7(23%) patients complained of pain at initial follow-up (5 right iliac fossa pains and 2 backache). These were managed conservatively. However subsequent management could not be found through the notes.

1 patient has been re-referred from general practitioner with persistent spotting per vaginum. On examination she was found to have granulation tissue and a stitch was removed from that area and local estrogen was prescribed. There was no evidence of mesh exposure.

1 patient underwent laparoscopic adhesiolysis due to ongoing abdominal pain and difficulty in defecation/painful defecation.

1 patient with long term pre-existing abdominal/back pain continued to have lower abdominal pain and backache post-operatively, so it was difficult to establish whether the SCP had contributed further. She was found to have a small (3 cm) pre-sacral collection which was managed conservatively and resolved. This patient also had a concomitant rectopexy.

**Long term:** LSCP (n=7) 2 (16%) patients had mesh exposure. They both required trimming of mesh and one of them underwent posterior vaginal prolapse repair due to new onset recto-enterocele.

OSCP (n=5)

There were no cases of mesh exposures in the OSCP.

One patient who had voiding dysfunction at short term follow up and required release of tape at 15 months postoperatively also underwent a further SCP (for vault recurrence) and rectopexy (associated rectal prolapse) just over 5 years after initial surgery for vault prolapse.

## Recurrence

8 (16%) patients required further POP surgery either for new prolapse or recurrence of apical prolapse.

However of these only 3 (6%) patients had recurrence of vault prolapse. 2 (5%) were in open SCP group (one at medium term and other at long term follow up) and 1 (8%) in LSCP (short term follow up). None of these patients originally had SCP for recurrence of vault prolapse.

This gives a recurrence rate (Table 2) for vault prolapse in our cohort of patients of 2% at short term, 2% medium term and 9% at long term follow up, although numbers here are small.

## Discussion

The reported success rate with ASCP is in the range of 78-100% [1-3]. Several studies have been done looking at short, medium and long term anatomical outcome of SCP and have quoted high success rates of 95% at 3 years or less 84% at 5 years and 74.7% at 13.5 years [6-13]. Studies have also shown that LSCP has high [14,15] and similar success rates to OSCP [5].

In our cohort the anatomical cure rate for vault pop was high at short term follow up (97.5%) and was maintained at medium term (97.5%) and long term follow up (93.7%). If we look at the overall success rate (need for further surgery for apical or other compartment prolapse after SCP) then success rate in our cohort was 97.9% at short term follow up, 92.6% at medium term follow up and 75% at long term follow up. This keeps up with the rates quoted in the current literature.

In the study by Hilger et al. the follow up most defects were noted in the anterior wall [12]. However in other studies [16-19] anatomical recurrence was confined to posterior compartment. In our study rate of new onset POP was low and most of the new onset prolapse was anterior vaginal wall. This may be because the LSCP involved placing mesh onto the post vaginal wall/cervix, and not supporting the anterior compartment. Most of the OSCP were performed for multi compartment descent (which included apical). Here the mesh was often used to support the apex but also anterior and/or posterior compartments as needed (using Y grafts). This may explain the lower incidence of new onset POP or recurrence of POP in this group of patients.

A recent RCT [5] concluded that there was no significant difference between open or laparoscopic SCP when duration of stay was compared as secondary outcome of their study. In our cohort of patients, although the inpatient hospital stay is shorter in the LSCP (median 2 days) as compared to OSCP group (median 3 days) the 2 groups do not appear to be comparable. Patients in OSCP have more associated co-morbidities and had more procedures done concomitantly, which is why they were deemed unsuitable for LSCP in the first instance.

Mesh exposure is a problematic complication with both OSCP and LSCP. Rate of mesh exposure after OSCP have been reported between 2% and 10% [1,20]. Similar rates have been reported in LSCP, although a recent review of more than 1000 cases reporting a mean rate of 2.7% [15]. Another however, found a substantially higher exposure rate of 10% with a rate of 23% in those patients undergoing concurrent vaginal hysterectomy [21].

In our study only 2 patients had mesh exposure giving a low the rate of mesh exposure 4.0%. Both these patients had LSCP and presented >5 years after their surgery. Both had vaginal hysterectomy in the past, and not at the time of their SCP, and underwent pelvic

floor repair along with the LSCP. In both of these cases procedure was performed vaginally assisted laparoscopic SCP, where the mesh was inserted vaginally [22].

An approach where the integrity of vaginal vault has been maintained had been hypothesised and proposed theoretically to decrease the incidence of mesh exposure in SCP. In a recent study by William et al with median follow up of 26 weeks concluded that preserving the vault integrity led to lower incidence of mesh exposure in patient undergoing LSCP and when hysterectomy was indicated supracervical technique should be considered as the incidence of mesh exposure was lower. If cervix needs to be removed due to various reasons then (vaginal assisted laparoscopic sacrocolpopexy) transvaginal attachment of mesh has lower rate of mesh exposure compared to (vaginal hysterectomy laparoscopic sacrocolpopexy) [23].

In our cohort 19/49 (39%) patients had concomitant hysterectomies performed at the time of SCP (open and laparoscopic approach). They were all subtotal hysterectomy (supracervical) with preservation of cervix done to allow mesh anchoring and potentially decrease mesh exposure. 10/12 (83%) patient in LSCP group had vaginal assisted LSCP where vault was opened, whereas in OSCP vault was not opened in any of the patients. This might have led to overall lower incidence of mesh exposure in our cohort with the low (0%) incidence of mesh complications in our OSCP group but a higher rate of 16% in the LSCP group.

We defined success at medium and long-term as patient need for further surgery or representation with POP. Because of the electronic system we determined that all, apart from the 10 patients where the case notes were destroyed, still lived within the health board region. We were therefore able to identify presentations with recurrences within the NHS, regardless of hospital. We cannot however exclude treatment within the private sector.

There are limitations for our study. We were unable to review 30% of our cases which affected our cohort size, especially in the long term follow-up where notes had been destroyed. Clinical outcome were based solely on the surgeons documentation of his or her own outcomes. There was no validated questionnaire to assess pre and post procedure outcomes. Our long term follow up however is long, though the numbers in this group is small.

## References

1. Nygaard IE, McCreery R, Brubaker L, Connolly A, Cundiff G, et al. (2004) Abdominal sacrocolpopexy: a comprehensive review. *Obstet Gynecol* 104: 805-823.
2. Flynn BJ, Webster GD (2002) Surgical management of the apical vaginal defect. *Curr Opin Urol* 12: 353-358.
3. Maher CF, Qatawneh AM, Dwyer PL, Carey MP, Cornish A, et al. (2004) Abdominal sacral colpopexy or vaginal sacrospinous colpopexy for vaginal vault prolapse: a prospective randomized study. *Am J Obstet Gynecol* 190: 20-26.
4. Pantazis K, Freeman R, Thomson A, Frappell J, Bombieri L, et al. (2013) Open and laparoscopic sacrocolpopexy demonstrate clinical equivalence: one year results from the las trial, an rct comparing the two approaches for treating post hysterectomy vault prolapse.
5. Onol FF, Onol SY (2012) Review of extraperitoneal sacrocolpopexy as a technique for advanced uterine and vault prolapse. *Curr Opin Obstet Gynecol* 24: 253-258.
6. Feldman GB, Birnbaum SJ (1979) Sacral colpopexy for vaginal vault prolapse. *Obstet Gynecol* 53: 399-401.
7. Addison WA, Livengood CH 3rd, Sutton GP, Parker RT (1985) Abdominal sacral colpopexy with Mersilene mesh in the retroperitoneal position in the management of posthysterectomy vaginal vault prolapse and enterocele. *Am J Obstet Gynecol* 153: 140-146.
8. Drutz HP, Cha LS (1987) Massive genital and vaginal vault prolapse treated by abdominal-vaginal sacropey with use of Marlex mesh: review of the literature. *Am J Obstet Gynecol* 156: 387-392.
9. Snyder TE, Krantz KE (1991) Abdominal-retroperitoneal sacral colpopexy for the correction of vaginal prolapse. *Obstet Gynecol* 77: 944-949.
10. Timmons MC, Addison WA, Addison SB, Cavenar MG (1992) Abdominal sacral colpopexy in 163 women with posthysterectomy vaginal vault prolapse and enterocele. Evolution of operative techniques. *J Reprod Med* 37: 323-327.
11. Podratz KC, Ferguson LK, Hoverman VR, Lee RA, Symmonds RE (1995) Abdominal sacral colpopexy for posthysterectomy vaginal vault descensus. *J Pelvic Surg* 1: 18-23.
12. Hilger WS, Poulson M, Norton PA (2003) Long-term results of abdominal sacrocolpopexy. *Am J Obstet Gynecol* 189: 1606-1610
13. Jeon MJ, Moon YJ, Jung HJ, Lim KJ, Yang HI, et al. (2009) A long-term treatment outcome of abdominal sacrocolpopexy. *Yonsei Med J* 50: 807-813.
14. Granese R, Candiani M, Perino A, Romano F, Cucinella G (2009) Laparoscopic sacrocolpopexy in the treatment of vaginal vault prolapse: 8 years experience. *Eur J Obstet Gynecol Reprod Biol* 146: 227-231.
15. Ganatra AM, Rozet F, Sanchez-Salas R, Barret E, Galiano M, et al. (2009) The current status of laparoscopic sacrocolpopexy: a review. *Eur Urol* 55: 1089-1103.
16. Claerhout F, De Ridder D, Roovers JP, Rommens H, Spelzini F, et al. (2009) Medium-term anatomic and functional results of laparoscopic sacrocolpopexy beyond the learning curve. *Eur Urol* 55: 1459-1467.
17. Higgs PJ, Chua HL, Smith AR (2005) Long term review of laparoscopic sacrocolpopexy. *BJOG* 112: 1134-1138.
18. Paraiso MF, Walters MD, Rackley RR, Melek S, Hugney C (2005) Laparoscopic and abdominal sacral colpopexies: a comparative cohort study. *Am J Obstet Gynecol* 192: 1752-1758.
19. Baessler K, Schuessler B (2001) Abdominal sacrocolpopexy and anatomy and function of the posterior compartment. *Obstet Gynecol* 97: 678-684.
20. Cundiff GW, Varner E, Visco AG, Zyczynski HM, Nager CW, et al. (2008) Risk factors for mesh/suture erosion following sacral colpopexy. *Am J Obstet Gynecol* 199: 688.
21. Tan-Kim J, Menefee SA, Luber KM, Nager CW, Lukacz ES (2011) Prevalence and risk factors for mesh erosion after laparoscopic-assisted sacrocolpopexy. *Int Urogynecol J* 22: 205-212.
22. Rae D, Hawthorn R (2002) Sacrocolpopexy for vaginal vault prolapse: a combined vaginal and laparoscopic approach. *Gynaecological Endoscopy* 11: 75-79
23. Warner WB, Vora S, Hurtado EA, Welgoss JA, Horbach NS, et al. (2012) Effect of Operative Technique on Mesh Exposure in Laparoscopic Sacrocolpopexy. *Female Pelvic Med Reconstr Surg* 18: 113-117

Citation: Tyagi V, Hawthorn R, Guerrero K (2013) Sacrocolpopexy (SCP) - A Cohort Study Looking at Short, Medium and Long Term Outcome. Med Surg Urol 2: 118. doi:10.4172/2168-9857.1000118