

Intraperitoneal Rupture of Urinary Bladder – A Diagnostic Conundrum

Sandeep Gupta, Navin Kumar Ram* and Nirupama Bansal

Banaras Hindu University, Varanasi, India

Abstract

Objective: To assess cause, demographic profile, presentation and optimal management in patients sustaining intraperitoneal rupture of urinary bladder. Bladder injuries are commonly seen in patients sustaining fracture of pelvis following road traffic accidents which are usually extraperitoneal. So it needs very high index of suspicion to diagnose bladder injury not associated with pelvic fracture.

Methods: We prospectively studied four patients who presented to us and were diagnosed to have intraperitoneal rupture of urinary bladder for their demographic profile, symptoms and signs at presentation and time delay in presentation. Investigations were done to assess their renal function and serum electrolytes. Retrograde cystography was done to make a final diagnosis in all the patients.

Results: All the patients were young males who sustained the blunt injury to lower abdomen. 3 out of 4 patients presented with distended abdomen and absent bowel sounds. Investigations revealed evidence of reverse autodialysis. All the patients showed extravasation of contrast material on retrograde cystography. One patient who was kept on conservative treatment had persistent symptoms on removal of per urethral catheter. All the patients underwent closure of bladder rent on laparotomy and improved after surgery.

Conclusion: The diagnosis of intraperitoneal rupture of urinary bladder should be considered in all patients who present with injury to the lower abdomen on full bladder with history of haematuria. They should be investigated with retrograde cystography and immediate repair of bladder tear should be performed to prevent the leakage of urine into the peritoneal cavity. Conservative management is usually not successful.

Keywords: Bladder rupture; Cystogram; Pseudo renal failure; Pelvic fracture

Introduction

Rupture of urinary bladder following abdominal trauma can be extraperitoneal or intraperitoneal. Extraperitoneal rupture of bladder occurs mostly in association with pelvic fracture [1]. It occurs on the lateral wall where the fascial attachments attach it to the pelvic walls or a bony spicule which directly lacerates the organ. Intraperitoneal rupture of bladder can occur spontaneously or following trivial trauma to the lower abdomen when the bladder is full. When left untreated, the isolated intraperitoneal rupture is uniformly fatal [2]. The diagnosis is not always straightforward and the old adage that to make a diagnosis one must think about it continues to be true for bladder rupture.

Material and Methods

We prospectively studied four cases diagnosed to have sustained intraperitoneal rupture of urinary bladder. The patients were studied for the demographic profile, inciting factors causing rupture of bladder, time to presentation, symptoms and signs at presentation, blood and imaging studies done, and management done for the patient. We tried to ascertain the optimal management for the patients who develop intraperitoneal rupture of urinary bladder (Tables 1 and 2).

Case No. 1

31 year old male was admitted in the surgical department with history of pain in lower abdomen which had spread to the whole abdomen following a physical assault 6 days back, after an alcohol binge. There was history of progressively increasing distension abdomen and passage of small amount of reddish urine. Patient was not history of vomiting or constipation. Examination revealed a pulse rate of 114/min., BP 100/60 mmHg, and temp of 101°F. His abdomen was massively distended, tense and tender. A provisional diagnosis of acute abdomen due to bowel injury was kept and he was catheterised to monitor his

urine output. After per urethral catheterisation it drained 4.5 litres of blood stained urine and the distension of abdomen disappeared. Investigations were done which are detailed in table 3. X-ray of the abdomen and pelvis did not reveal any bony pelvic injury. Cystogram revealed extravasation of contrast material in the peritoneal cavity. A diagnosis of intraperitoneal rupture of urinary bladder was made and surgery revealed a 6cm rent in the dome of urinary bladder through which foley catheter was coming out to lie in the peritoneal cavity. The bladder was repaired in two layers using vicryl 3-0 and per-urethral catheter was kept for 2 weeks. Following catheter removal the patient could pass urine well and remained alright.

Case No. 2

A 30 year old gentleman wakes up in night to pass urine and fell down from the roof about 15 feet high where he was sleeping after alcohol ingestion. He was admitted to the nearby hospital with fracture of ulna and inability to pass urine, lower abdominal pain and distension lower abdomen. He was catheterised which was kept for 10 days and later removed. But again after the catheter removal, he was unable to pass urine and started developing pain abdomen. Hence, he was catheterised again and was referred to us. His examination was normal and investigations are noted in table 3. There was no microscopic haematuria on urine examination. Cystogram was done which revealed hourglass appearance (Figure 1). He was operated to close the defect

***Corresponding author:** Dr Navin Kumar Ram, MDF, RN: 13, Banaras Hindu University, Varanasi, 221005, India, E-mail: doctornavin123@gmail.com

Received September 09, 2012; **Published** February 22, 2013

Citation: Gupta S, Ram NK, Bansal N (2013) Intraperitoneal Rupture of Urinary Bladder—A Diagnostic Conundrum. 2: 660. doi:10.4172/scientificreports.660

Copyright: © 2013 Gupta S, et al. This is an open-access article distributed under the terms of the Creative Commons Attribution License, which permits unrestricted use, distribution, and reproduction in any medium, provided the original author and source are credited.

SNo	Age (yrs)	Sex	Cause	Influence	Time of presentation	Pain	Distension	Difficulty in passing urine	Haematuria	Associated Injuries
1	31	M	Assault	Alcohol	6days	+	++++	+		-
2	31	M	Fall	Sleep	10days	-	-	On catheter	For initial 2 days	Fracture ulna
3	40	M	Assault	Alcohol	2days	+	++	+	+	-
4	27	M	Assault	Alcohol	4days	+	++++	+	+	-

RR: Respiration rate: BP: Blood pressure

Table 1: Showing demographic profile, cause of injury and its presenting features.

	Pulse	BP	RR	Temperature	Abdominal distension	Bowel sounds	Urine drained on first catheterisation
Case 1	114	100/60	26	101 F	++++	Absent	4 Litres
Case 2	84	128/84	16	98 F	--	+	No record
Case 3	136	96/70	30	99 F	+++	Absent	100 ml
Case 4	132	90/60	40	102	++++	Absent	3 Litres

Table 2: Signs at the time of presentation.

Case No.	Sodium (mEq/dl)	Potassium (mEq/dl)	Creatinine (mg/dl)	Urea (mg/dl)	USG
1	129	6.0	4.2	136	Free fluid and bladder empty
2	138	4.8	1.2	38	On catheter. Normal with bladder empty
3	130	5.3	3.0	79	Free fluid with bladder empty
4	122	6.5	9.0	306	Free fluid with bladder empty

Table 3: Showing renal function tests and electrolytes at presentation.

which was 5 cm wide in the dome of the urinary bladder. There were adhesions present in the pelvis from which the bladder was dissected. Perurethral catheter was kept for 12 days and no extravasation was seen on the cystogram done before removal of catheter.

Case No. 3

A 40 year gentleman was admitted to the Emergency department with history of fall 2 days back while running during a scuffle after alcohol intake. He developed pain and progressive distension following it. He was catheterised in a nearby hospital and only small amount of blood stained urine was drained. He was sick looking with pulse 136/min. respiratory rate of 30/min and Bp 96/70 mmHg. His abdomen was grossly distended with guarding and rigidity and bowel sounds were absent. His investigations were done which revealed Haemoglobin 7gm/dl, Total leucocytes count 14700, Neutrophilia of 81%, blood urea of 69 mg/dl, serum creatinine 3 mg/dl, potassium 5.3 mEq/L, sodium 130 mEq/L. A provisional diagnosis of bowel injury with dehydration was made and the patient was resuscitated with 4 litres of intravenous fluid but his urine output remained 100 ml and his abdominal distension further increased. His blood urea was 86 mg/dl and serum creatinine 4.9 mg/dl. Ultrasonography revealed free fluid in the peritoneal cavity and the urinary bladder was empty. Peritoneal tap revealed haemorrhagic fluid. A cystogram revealed hourglass appearance suggestive of extravasation of contrast material. A diagnosis of intraperitoneal rupture of urinary bladder was made and exploration revealed 4 litres of blood stained urine in the peritoneal cavity. A 2cm defect in the dome of the urinary bladder was found which was repaired in two layers using vicryl 3-0 suture and a perivesical drain was placed. Catheter was removed on 14th postoperative day.

Case No.4

27 years male was involved in a brawl after a bout of alcohol 10 days back in his village located in remote mountainous region. He presented to us 4 days later with hugely distended abdomen and difficulty in breathing. His pulse was 132 min, BP was 90/60 mmHg and respiratory rate was 40/min. Abdomen was hugely distended, tense and tender and bowel sound were absent and gross ascites was present. He was catheterised and it drained 5 litres of dirty haemorrhagic fluid. His

investigations at presentation are detailed in (Table 3). A diagnosis of intraperitoneal rupture of urinary bladder was kept. Ultrasonography of the abdomen revealed free fluid in the peritoneum and the catheter was found lying in the peritoneal cavity at surgery. A 4cm rent in the dome of urinary bladder was sutured in a water tight fashion. No other intraperitoneal injuries were noted.

Discussion

Bladder injuries are frequently present with blunt and penetrating injuries to the abdomen. It has been reported to occur in 5-12% patients with blunt injuries [3]. Traumatic bladder injuries are more frequently extraperitoneal than intraperitoneal. Peters found 58% injuries to be extraperitoneal, 34% to be intraperitoneal and 8% to be a combination of both. Intraperitoneal rupture of urinary bladder occurs when there is sudden rise in the intravesical pressure in a full bladder, leading to rupture of the dome. The dome is least supported of the full bladder walls, having its muscle fibres widely separated and offering the least resistance to a sudden change in intravesical pressure [4]. This leads to urinary ascites, elevation of levels of serum creatinine and blood urea, potassium and metabolic acidosis due to absorption of urine by the peritoneum, a picture called pseudo-renal failure [5]. An intravesical pressure of more than 300cm of water is required to rupture a normal bladder. Rupture may be seen much more readily if the bladder wall is weakened by some pathology such as previous surgery or pelvic irradiation. None of our patients had any such predisposing factor weakening their bladder wall.

As usually the trauma involved is trivial, it is often difficult to differentiate it from other conditions causing distension of abdomen like bowel perforation with peritonitis or intestinal obstruction. Hence, a high index of suspicion is required. Features which point toward the bladder rupture include history of trauma to lower abdomen, inability to pass urine or oliguria, haematuria, progressive distension of abdomen due to increasing ascites, rising renal parameters and drainage of large amount of urine on bladder catheterisation [3]. In case no 3 litres urine drained on catheterisation which may be because of the small perforation in the bladder. In case no 1 and 4, a large amount of haemorrhagic urine could be drained on catheterization. At the time of surgery the catheter was found to be lying in the

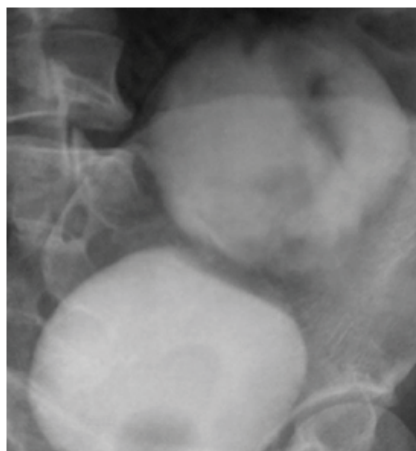


Figure 1: Cystogram showing hour glass appearance in a patient with a intraperitoneal rupture of urinary bladder.

peritoneum which means that the extravasated urine was thus drained from the peritoneum. The serum urea, creatinine and potassium levels was found elevated and levels of serum sodium was less after 24 hrs. It occurs because of the reabsorption of various solutes excreted in urine occurs towards the concentration gradient, also termed reverse autodialysis. The longer the time to presentation the more severe are the biochemical alterations. Case no. 2 did not have typical biochemical alterations because he was put on continuous bladder drainage before he presented to us.

Gross or microscopic haematuria is a useful indicator of genitourinary tract injury but there may be absence of haematuria in 15% patients with intraperitoneal rupture of urinary bladder [6]. Only one of our patients did not have haematuria (case no. 2) which may be because he was managed at some other centre for the initial 10 days.

Diagnosis can be confirmed by retrograde cystography which if carefully performed can detect intraperitoneal rupture bladder in 100% cases. However, it can miss the diagnosis if post void films are not taken. Carroll noted that in 13% patients extravasation could be seen in post drainage films alone [7]. For cystography the bladder should be filled with at least 350-450ml of contrast material to allow adequate distension. In cases of intraperitoneal rupture of urinary bladder a cystogram will show contrast collecting within the peritoneal cavity and outlining bowel loops which appear as cylindrical filling defects. When the patient is in supine position free intraperitoneal contrast settles in the most dependent portion of the pelvis and the cystogram shows hourglass appearance as was seen in our patients (Figure 1). In hour glass appearance well defined lower portion represents the urinary bladder and the upper part is formed by the free contrast in peritoneal cavity.

CT is an important tool for the evaluation of the patient with multiple traumas. However, it was not found to be a reliable method to evaluate for bladder rupture [8]. However, repeating pelvic scanning after bladder drainage and filling the bladder with dilute contrast fluid may enhance the accuracy of CT in this scenario [9].

Treatment of the patients with intraperitoneal rupture urinary bladder involves surgical exploration with primary closure of the defect. We found that conservative management of our case no. 2 who was kept on continuous bladder drainage for 10 days failed and he underwent closure of the defect at surgery. After closure of the defect

the biochemical abnormalities normalize rapidly within a day and patients improved without any complications. At the time of surgery the bladder should be thoroughly inspected transvesically for a second laceration which may leak urine later on if missed.

Laparoscopic repair of rupture bladder has been reported to be feasible in well selected patients with no other intrabdominal injuries which offer faster recovery and better cosmetic results [10].

Conclusion

Intraperitoneal rupture of urinary bladder is an uncommon condition which if left untreated can be fatal. A high index of suspicion should be kept in patient sustained lower abdominal injury with full bladder and present with lower abdominal pain and distension abdomen. Diagnosis can made appropriately using retrograde cystography and taking postdrainage films. The patients with intraperitoneal rupture are optimally managed by surgical closure of the defect in the urinary bladder in a water tight fashion.

References

1. Corriere JN Jr, Sandler CM (1986) Management of the ruptured bladder: seven years of experience with 111 cases. *J Trauma* 26: 830-833.
2. Scholl AJ (1936) Rupture of the urinary bladder associated with prostatic hypertrophy. *JAMA* 106: 701-704.
3. Peters PC (1989) Intraperitoneal rupture of urinary bladder. *Urol Clin North Am* 16: 279-282.
4. Oliver JA, Taguchi Y (1982) Rupture of the full bladder. *J Urol* 128: 25-26.
5. Jerwood DC, Mason NP (1995) Pseudo-renal failure after traumatic bladder rupture—the common features. *Br J Urol* 76: 406-407.
6. Cass AS, Luxenberg M (1987) Features of 164 bladder ruptures. *J Urol* 138: 743-745.
7. Carroll PR, McAninch JW (1983) Major bladder trauma: the accuracy of cystography. *J Urol* 130: 887-888.
8. Mee SL, McAninch JW, Federle MP (1987) Computerized tomography in bladder rupture: diagnostic limitations. *J Urol* 137: 207-209.
9. Horstman WG, McClennan BL, Heiken JP (1991) Comparison of computed tomography and conventional cystography for detection of traumatic bladder rupture. *Urol Radiol* 12: 188-193.
10. Kim FJ, Chammas MF Jr, Gewehr EV, Campagna A, Moore EE (2008) Laparoscopic management of intraperitoneal bladder rupture secondary to blunt abdominal trauma using intracorporeal single layer suturing technique. *J Trauma* 65: 234-236.