

# Standardized Low Resolution Electromagnetic Tomography (s\_LORETA) is a Sensitive Indicator of Protracted Neuropsychological Impairments Following “Mild” (Concussive) Traumatic Brain Injury

Paula L Corradini and Michael A Persinger\*

Departments of Psychology and Biology, Laurentian University, Sudbury, Ontario, Canada

## Abstract

**Background:** Differentiation of patients who have sustained a mild TBI and who show continued difficulties with adaptation is a major clinical challenge and a time-consuming process when classical neuropsychological testing is involved. LORETA (Low Resolution Electromagnetic Tomography) was employed to discern its sensitivity for differentiating the regions of the cerebrum for patients who exhibited continued difficulties with adaptation and showed either no or formal neuropsychological impairment years after the injury.

**Methods:** The quantitative electroencephalographic data for total of 14 patients who had sustained a mild TBI and who either displayed moderately-severe neuropsychological impairment (n=7) or did not (n=7) according to the results of a standardized battery were analyzed by s\_LORETA software. The centroid Talairach (X,Y,Z) components for each major frequency band that were significantly different between the two populations were computed.

**Results:** Averaged s\_LORETAs demonstrated that the group of patients who displayed formal moderate-severe neuropsychological impairments more than five years after the injury displayed differential power values compared to the group of patients who also sustained a TBI but exhibited no formal impairment within regions that were consistent with the residual subjective symptoms. The s\_LORETA analyses, including data collection, required less than 1 hr.

**Conclusion:** A 30 minute sample of QEEG data when applied to s\_LORETA software can reveal the general regions of the cerebrum that remain anomalous for years after the initial injury. Employment of this technology could be more efficient and provide greater precision for the strategic interventions that could facilitate the patients' adaptation.

**Keywords:** s\_LORETA; Quantitative electroencephalography; TBI; Mild brain injury; Neuropsychological assessments; Protracted delays in adaptation

## Introduction

Traumatic Brain Injury (TBI), particularly Closed Head Injuries (CHI) where there is no conspicuous damage or fracture of the skull, produces a non-linear effect upon the patient's adaptation, productivity, and quality of life [1]. The capricious consequences from the dispersions of mechanical forces and energies through cerebral space can result in a continuum of changes that range from no discernable or overt alterations to severe psychopathologies. Whereas subtle alterations, such as “changes in personality” may require years to evolve and may be discernable primarily by the immediate caregivers, more conspicuous manifestations such as depression, subjective experiences of loss of “the self” [2], somatic complaints, and most significantly the diminished capacity to reconstruct experiences (autobiographical memory) may be predominant the patient's profile. These pernicious changes can be present for years following a closed head injury even though the person appears “normal”. The cerebral correlates of these changes are expected to be dynamic, more electrical and chemical rather than structural, and require sensitive technologies to be discerned.

Although visibly obvious changes in cerebral structure have been well documented by both CT (Computerized Tomography) and MRI (Magnetic Resonance Imaging) for severe brain injuries [3] the cerebral correlates and substrates for “mild” TBIs that include “concussions” or episodes following mechanical impact to the skull when there was *not* a suspension of consciousness have been more difficult to verify with these methods [4]. Yet more or less permanent neuropsychological impairments occur in a large subpopulation of patients who have sustained such injuries. Test-retest studies involving patients who sustained cerebral impacts from motor vehicle incidents

have shown there is very little change in impairment after about one year, that is, almost no “improvement” or “recovery” even when years have elapsed since the initial impact [5]. The pattern was also noticed in a subpopulation of athletes who had sustained concussive injuries; almost half the number of that population had not returned to previous employment more than a decade later [6].

Roberts and his colleagues [7,8] were among the first to identify that serial concussive injuries from proximal explosions during military operations resulted in long term disabilities associated with neuropsychological impairments and the emergence of a syndrome that was similar to complex partial epilepsy, but without the display of overt electrical seizures or convulsions. This “Epileptic Spectrum Disorder” was associated with abnormal elevations on multiple psychometric scales by which psychologists infer psychopathology. Roberts and his colleagues demonstrated that these patients display enhanced theta activity [9], similar to that exhibited during interictal periods by verified complex partial epileptic patients. The symptoms were partially

**\*Corresponding author:** Clinical Neuroscience Laboratory, Behavioural Neuroscience Program, Departments of Psychology and Biology, Laurentian University, Sudbury, Ontario, Canada P3E 2C6, Tel: 01-705-675-4824; Fax: 01-705-671-3844; E-mail: [mpersinger@laurentian.ca](mailto:mpersinger@laurentian.ca); [pl\\_corradini@laurentian.ca](mailto:pl_corradini@laurentian.ca)

**Received** October 31, 2013; **Accepted** November 26, 2013; **Published** December 04, 2013

**Citation:** Corradini PL, Persinger MA (2013) Standardized Low Resolution Electromagnetic Tomography (s\_LORETA) is a Sensitive Indicator of Protracted Neuropsychological Impairments Following “Mild” (Concussive) Traumatic Brain Injury. J Neurol Neurophysiol 4: 176. doi:10.4172/2155-9562.1000176

**Copyright:** © 2013 Corradini PL, et al. This is an open-access article distributed under the terms of the Creative Commons Attribution License, which permits unrestricted use, distribution, and reproduction in any medium, provided the original author and source are credited.

responsive to anticonvulsants such a carbamazepine (Tegretol) but at dosages lower than those prescribed for classical epileptic patients. Many if not most of their patients had been attributed diagnoses such as Post-Traumatic Stress Disorder, Borderline Personality Disorder or some variant of an affective disorder.

Gorman and Persinger [10] reported that patients who sustained TBIs from mechanical impacts to the skull but with either no suspension of consciousness or suspension for less than 10 min, reported extreme elevations in reported signs and symptoms that reflected the Epileptic Spectrum Disorder. The major proportion of the patients who displayed mild to moderate neuropsychological impairment also displayed these marked elevations. In a subpopulation of military personnel who had been exposed within the previous two to three years to repeated concussive injuries from proximal explosions, the concurrence was particularly elevated. Previous clinical trials for patients who had sustained mild to moderate TBIs but who had not returned to employment because of “continued difficulties” with depression, deficits in memory, and markedly diminished rate of cognitive processing, indicated marked subjective improvement with carbamazepine which also improved mood [11]. Subsequent unpublished studies indicated similar improvements, particularly diminished pain, with low dosages of GABA-pentin (Neurontin).

Although neuropsychological assessments involving standardized, performance-based tests can be very revealing with respect to the magnitude of the deficits and the class of behavioral weakness displayed by the patient, a thorough assessment requires more than 10 to 12 hours over a two day period in order to accommodate factors such as motivation, inter-test reliability and validity, and persistence. Recently Corradini and Persinger [12] found that the employment of s\_LORETA or standardized Low Resolution Electromagnetic Tomography was remarkably sensitive to revealing activation of regions of the cerebrum associated with the most powerful components of the neuropsychological test battery. For healthy young adults s\_LORETA revealed frequency specific changes in power: (1) within the right prefrontal region during engagement of the Category Test, (2) within the left superior temporal region during the Speech-Sounds Test, and (3) within the medial prefrontal region during toe Graphaesthesia activation. This method of analysis has also been employed in clinical paradigms in order to explore differences between varying “mental illnesses”. By employing this analysis, differences in the pattern of activation has been found between clinical populations. Dementia [13], Huntington’s disease [14], and depression [15] have all been explored using LORETA technology and each study has found a different pattern of activation depending on the population.

In the present study we compared the s\_LORETA profile of patients who had sustained a mild TBI during the previous years and did not display formal neuropsychological impairments with patients who sustained a mild TBI during the same previous period but who displayed moderate to severe neuropsychological impairment. Here we show the clear sensitivity of s\_LORETA, which requires less than an hour of data collection and analyses, to differentiate the two populations.

## Materials and Methods

### Patient history and data base

We randomly selected 26 patients from our data pool; the mean age was 40 years. The mean and standard deviations for the delays between the mechanical impacts to the skulls and the assessments was about 6 years with a range between 0.3 and 16 years. All of them had been

referred by external agencies for a full neuropsychological assessment to discern the level of functioning following a closed head injury due to an impact of concussive force or mechanical energies. They all met the criteria of mild TBI on the bases of either a GSC of >13 or a suspension of consciousness of less than 20 min.

The patients had been administered our standard battery [5] of intellectual, memory, academic achievement, classic (Halstead-Reitan Battery) and novel (e.g. Conditioned Spatial Association Test) neuropsychological tests. They were partitioned into groups according to the Halstead-Reitan Impairment Index. For the present study we selected those with indices of less than 0.3 (no impairment) and those with indices of >0.7 (moderate-severe impairment). This resulted in 7 patients per group. The gender ratios, age, and time since the original injury were comparable between groups. Because those individuals with a mild neuropsychological impairment (i.e. Halstead-Reitan Impairment Index between 0.3 and 0.7) occupied an intermediate position between those who had no formal neuropsychological impairment and those individuals with a moderate to severe neuropsychological impairment they were removed from the database so only the extremes of our population were examined. This resulted in 7 patients per group with comparable gender ratios, age and time since original injury.

Table 2 shows pertinent patient information (e.g. age, sex, time since injury, overall Halstead-Reitan Impairment Index). The overall Halstead impairment index is an aggregate score of 7 classical neuropsychological tests that summarizes the overall neurocognitive functioning at the time of the assessment (a score of 0 would indicate no evidence of a formal neuropsychological impairment while a score of 1 would indicate a severe neuropsychological impairment). The individuals who scored in the moderate to severe range displayed a global impairment and typically demonstrated difficulty adapting to the demands of daily life (Table 2).

### Procedure

The QEEG data were collected in the final hour of the first day of a two day assessment and required about 30 min. During the QEEG the patient sat in a comfortable chair in a dimly lit acoustic chamber. The patient could communicate at any time with the EEG technicians through a microphone and speaker system. The first phase of the QEEG collection was an eyes-open baseline (10 min). The client was asked to pick a spot on the wall in front of them and focus on that spot. They were told they could blink as much as needed but to try and remain as still as possible throughout the duration of the testing. The patient was then asked to close their eyes and to relax; the lights were dimmed. After the eyes-closed portion the client was asked to keep their eyes closed and breathe deeply but very slowly for approximately 45 seconds. After the 45 seconds they told they could relax keeping their eyes closed. After 30 seconds of relaxation they were again asked to deep breath for 45 seconds at a slightly increased pace and then they were asked to relax. Finally they were asked to breathe deeply a third time again at a slightly increased pace for 45 seconds before relaxing.

### Quantitative electroencephalography

Brain activity was measured by a Mitsar-201 portable QEEG system that was connected to a 19-channel electrode cap (Electrode-Cap International) that contained the 10-20 Standard Electrode Placement. Electrode site include Fp1, Fp2, F7, F3, Fz, F4, F8, T3, C3, Cz, C4, T4, T5, P3, Pz, T6, O1, and O2 that were linked to the ears (A1 and A2) for monopolar recordings. Impedance of all channels was less than 10 kOhm. Data were acquired using WinEEG v2.84.44 software

with a sampling rate of 250 Hz. A 50 Hz to 70 Hz notch filter was used in the WinEEG software for all subjects in order to filter high frequency noise during recording. The EEG record was inspected for movement artifacts; the principal component analyses (PCA) method of artifact correction within WinEEG software was employed where appropriate [16].

### Source localization (s\_LORETA)

Source localization analyses were completed by standardized low-resolution electromagnetic tomography or s\_LORETA [17] for 10 samples of QEEG data. These epochs were divided into 2 s segments that did not overlap for the purposes of analyses. Cross-spectral analyses were completed on all epochs. Independent t-tests without normalization were utilized within s-LORETA to discern source localization throughout the telencephalon for each of the software’s defined frequency bands which included delta (1.5-4 Hz), theta (4-7.5 Hz), alpha-1 (7.5 to 10 Hz), alpha-2 (10-13 Hz), beta-1 (13-20 Hz), beta-2 (20-25 Hz), beta-3 (25-30 Hz) and gamma (30 to 40 Hz). Group averages for the impairment and non-impaired patients were obtained. The centroids were expressed according to Talairach coordinates.

### Results

The differences in power between the TBI group that did not show formal neuropsychological impairment and the group that displayed moderate to severe impairment within specific regions cerebral space as inferred by s\_LORETA for the frequency bands, general cerebral locations (Brodmann areas), hemisphere, and Talairach coordinates are shown in Table 1. To more clearly elucidate these differences, the primary differentiating patterns are shown in subsequent figures. For brevity we will subsequently refer to the group that displayed the moderate to severe neuropsychological impairment as the impaired group and those that were not as non-impairment. However it is important to emphasize that both groups had sustained a mild TBI on average about five years before the measurement. In the figures, red to yellow indicates increased activation and blue represents decreased activation for the impaired individuals compared to the non-impairment group.

As can be seen in Figure 1A, the impaired group displayed increased activity within the delta band within the right medial frontal gyrus but decreased activation with the parahippocampal and posterior cingulate

Patient #	Sex	Age	Time since injury (years)	Halstead impairment index
1	Male	50	5	0.14
2	Male	20	0.7	0
3	Female	36	2	0.71
4	Female	38	7	0.28
5	Female	26	3	0
6	Female	50	4	1.0
7	Female	32	16	0.14
8	Female	49	4	0.71
9	Male	65	2	0.57
10	Male	20	0.7	0.14
11	Male	61	5	0.57
12	Male	18	0.3	0.28
13	Female	54	0.5	0.71
14	Male	32	4.5	0.57

**Table 1:** Patient Information.

Frequency	Activation	Region		Hemisphere	X	Y	Z
Delta	Increased	BA8	Medial Frontal Gyrus	Right	15	25	45
	Decreased	BA27	Parahippocampal Gyrus	Right	15	-35	0
	Decreased	BA30	Posterior Cingulate	Right	20	-60	10
Theta	Decreased	BA27	Parahippocampal Gyrus	Bilateral	+/-10	-35	0
	Decreased	BA30	Posterior Cingulate	Bilateral	+/-10	-50	0
Alpha1	Decreased	BA36/37	Parahippocampal Gyrus	Bilateral	+/-25	-35	0
	Decreased	BA19	Fusiform Gyrus	Bilateral	+/-25	-60	-15
	Decreased	BA20	Inferior Temporal Gyrus	Bilateral	+/-30	-5	-45
	Decreased	BA23/31	Cingulate Gyrus	Bilateral	+/-5	-25	35
Alpha2	Decreased	BA2	Postcentral Gyrus	Bilateral	+/-50	-30	40
	Decreased	BA40	Inferior Parietal Lobule	Bilateral	+/-45	-35	40
	Decreased	BA18	Middle Occipital Gyrus	Bilateral	+/-30	-95	-5
Beta1	Decreased	BA17/18/19	Lingual Gyrus	Bilateral	+/-10	-60	0
	Decreased	BA30	Posterior Cingulate	Bilateral	+/-5	-70	5
Beta2	Decreased	BA17/18	Lingual Gyrus	Bilateral	+/-5	-90	-20
	Decreased	BA18	Middle Occipital Gyrus	Left	-30	-95	-5
	Increased	BA6	Precentral Gyrus	Left	-65	-5	25
Gamma	Decreased	BA18/19	Lingual Gyrus	Bilateral	+/-15	-75	0
	Decreased	BA30	Posterior Cingulate	Bilateral	+/-15	-65	10
	Decreased	BA37	Parahippocampal Gyrus	Bilateral	+/-25	-35	0

**Table 2:** Frequency bands, direction of activation, region (Brodmann areas), general description, hemisphere and Talairach coordinates for impaired patients compared to those who were not impaired.



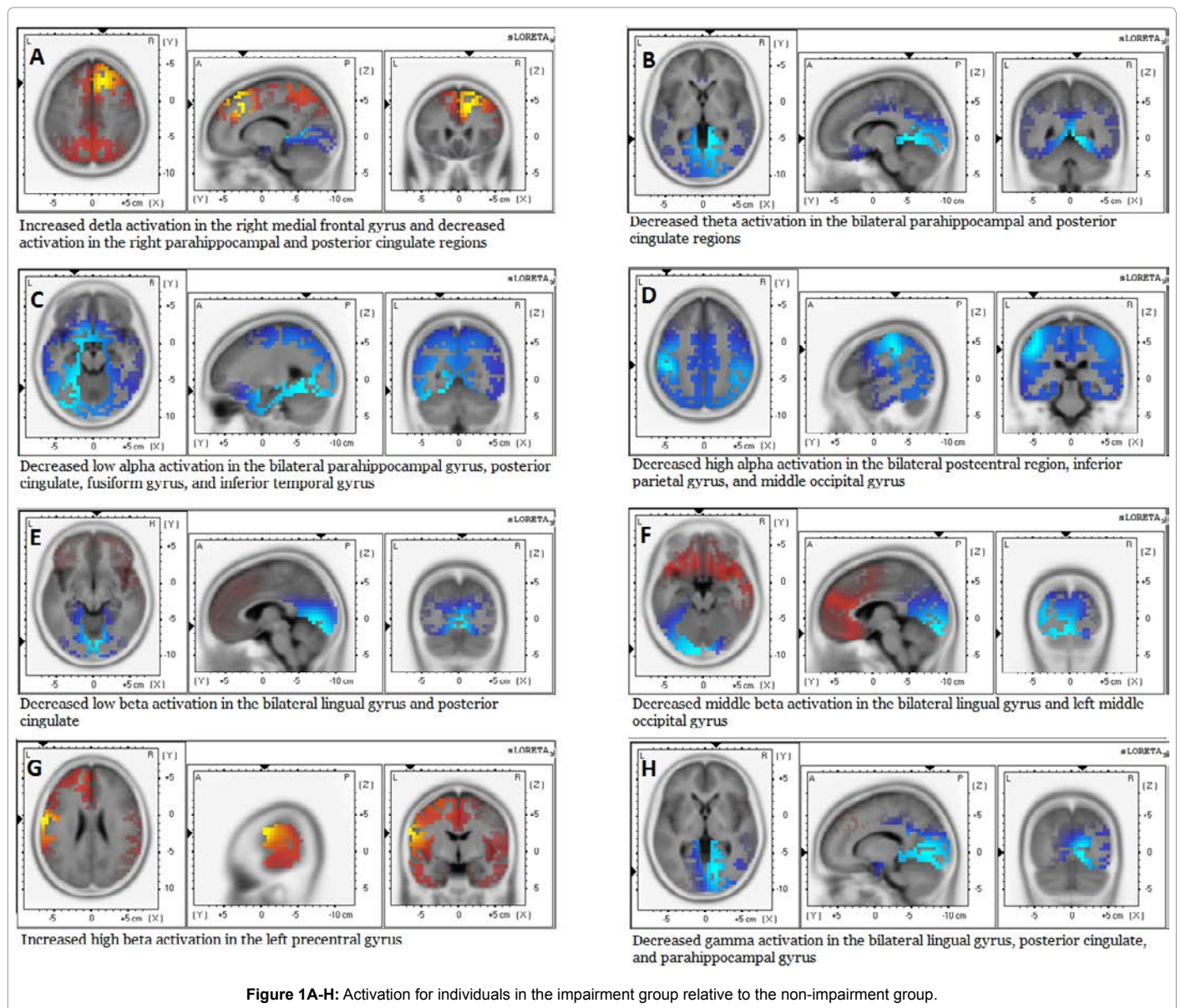
regions within that hemisphere. The decreased activity was also evident within the theta band bilaterally within the parahippocampal and posterior cingulate regions (Figure 1B). Within the lower half of the alpha frequency band the diminished activation involved these areas but also expanded into the fusiform (occipitotemporal) gyrus and the inferior temporal gyrus (Figure 1C).

The diminished power of activation remained present in the impaired group within the upper band of alpha activity which was regionalized to the parietooccipital region (Figure 1D). The diminished activity within the low beta activity band was centralized within the posterior cingulate and lingual gyrus for the impaired population compared to those who were not (Figure 1E). Finally the power within the faster beta activities, often associated with more complex types of cognition, were diminished for the impaired group within the lingual gyrus, left middle occipital region, and the left precentral gyrus (Figures 1F and 1G). For the gamma range, which is presumably associated with the processes coupled to consciousness (Figure 1H), the impaired

group displayed marked diminishment within the parahippocampal gyrus in particular.

## Discussion

To our knowledge this is one for the first quantitative comparisons of s\_LORETA profiles for mild TBI patients who either displayed formal moderate to severe neuropsychological impairment or no impairment years after the insult to the cerebrum. Without delineating the details for each patient’s face sheet from the neuropsychological assessment, the pattern of the diminished activity across the various frequency bands reflected the general reports and subjective experiences of the impaired group compared to the group that was not impaired. The impaired group’s major concern, rather than general difficulties with information processing and family interactions, was diminished autobiographical memory, decreased capacity to learn new information as quickly as they did before the TBI, less proficiency for remembering the faces of new acquaintances, and (at least perceived) delay of execution of tasks after rapid or novel visual presentations.



There is consistent experimental congruence with our results. The role of the right prefrontal region for reconstructing episodic memory, of which autobiographical memory is a subset, is well established [18]. Increased delta activity within this region would be expected to diminish the rates of reconstruction. The decreased power within the theta and low alpha band within the parahippocampal region and the adjacent temporal lobe would certainly be consistent with the diffuse difficulties reported by these patients to remember new information [19] since the injury at rates that were at least subjectively similar to before the injury. The coupling between the decreased power within the theta range and the gamma range within the parahippocampal gyrus, considering the importance of these two bands for the intercommunication between the cerebral cortices and the hippocampal formation, could accommodate the experiences of "detachment" of the individuals' present and past experiences [20].

The results of these analyses and the employment of s\_LORETA may be a critical tool that will differentiate patients who still exhibit difficulties with adaptation because of persistent anomalies in cerebral activity. These alterations would not necessarily be obvious by MRI and CT. The speed, inexpensive and non-invasive nature of the measurement, particularly if the validity is generalizable to larger populations, suggests this tool could be an excellent primary indicator. Our clinical group has now begun to develop procedures and protocols with the goal to generate profiles that allow more expeditious and accurate intervention strategies.

## References

1. Persinger MA (1995) Neuropsychological principia brevia: an application to traumatic (acquired) brain injury. *Psychol Rep* 77: 707-724.
2. Persinger MA (1993) Personality changes following brain injury as a grief response to the loss of sense of self: phenomenological themes as indices of local lability and neurocognitive structuring as psychotherapy. *Psych Repts* 72: 1059-1068.
3. Cooper PR (1993) *Head Injury*. William & Wilkins: Baltimore, MA, USA.
4. Parker RS (1990) *Traumatic brain injury and neuropsychological impairment*. Springer-Verlag: NY, USA.
5. Tiller SG, St-Pierre LS, Persinger MA (2013) Absence of quantitative improvement in neuropsychological profiles in patients who exhibit moderate brain impairment: comparisons of cross-sectional and longitudinal data (1 thru 4 years post-injury). *J Behav Brain Sci* 3: 225-238.
6. Levin HS, Grafman J, Eisenberg HM (1987) *Neurobehavioral recovery from head injury*. Oxford Press: NY, USA.
7. Roberts RJ, Gorman LL, Lee GP, Hines ME, Richardson ED, et al. (1992) The phenomenology of multiple partial seizure-like symptoms without stereotyped spells: an epilepsy spectrum disorder? *Epilepsy Res* 13: 167-177.
8. Hines ME, Kubu CS, Roberts RJ, Varney NR (1995) Characteristics and mechanisms of epilepsy spectrum disorder: an explanatory model. *Appl Neuropsychol* 2: 1-6.
9. Varney NR, Hines ME, Bailey C, Roberts RJ (1992) Neuropsychiatric correlates of theta bursts in patients with closed head injury. *Brain Inj* 6: 499-508.
10. Gorham R, Persinger MA (2012) Emergence of complex partial epilepsy-like experiences following closed head injuries: personality variables and neuropsychological profiles. *Epilepsy Behav* 23: 152-158.
11. Persinger MA (2000) Subjective improvement following treatment with carbamazepine (Tegretol) for a subpopulation of patients with traumatic brain injuries. *Percept Mot Skills* 90: 37-40.
12. Corradini PL, Persinger MA (2013) S-LORETA validity of classic and novel performance-based neuropsychological tests: the future of clinical neuropsychological assessment? (in submission).
13. Nishida K, Yoshimura M, Isotani T, Yoshida T, Kitaura Y, et al. (2011) Differences in quantitative EEG between frontotemporal dementia and Alzheimer's disease as revealed by LORETA. *Clin Neurophysiol* 122: 1718-1725.
14. Painold A, Anderer P, Holl AK, Letmaier M, Saletu-Zyhlarz GM, et al. (2011) EEG low-resolution brain electromagnetic tomography (LORETA) in Huntington's disease. *J Neurol* 258: 840-854.
15. Saletu B, Anderer P, Saletu-Zyhlarz GM (2010) EEG topography and tomography (LORETA) in diagnosis and pharmacotherapy of depression. *Clin EEG Neurosci* 41: 203-210.
16. Pascual-Marqui RD (2002) Standardized low-resolution brain electromagnetic tomography (sLORETA): technical details. *Methods Find Exp Clin Pharmacol* 24: 5-12.
17. Pascual-Marqui RD, Esslen M, Kochi K, Lehmann D (2002) Functional imaging with low-resolution brain electromagnetic tomography (LORETA): a review. *Methods Find Exp Clin Pharmacol* 24: 91-95.
18. Buckner RL, Petersen SE (1996) What does neuroimaging tell us about the role of prefrontal cortex in memory retrieval? *Sem Neurosci* 8: 47-55.
19. Young BJ, Otto T, Fox GD, Eichenbaum H (1997) Memory representation within the parahippocampal region. *J Neurosci* 17: 5183-5195.
20. Whitman JC, Ward LM, Woodward TS (2013) Patterns of Cortical Oscillations Organize Neural Activity into Whole-Brain Functional Networks Evident in the fMRI BOLD Signal. *Front Hum Neurosci* 7: 80.

**Citation:** Corradini PL, Persinger MA (2013) Standardized Low Resolution Electromagnetic Tomography (s\_LORETA) is a Sensitive Indicator of Protracted Neuropsychological Impairments Following "Mild" (Concussive) Traumatic Brain Injury. *J Neurol Neurophysiol* 4: 176. doi:10.4172/2155-9562.1000176

## Submit your next manuscript and get advantages of OMICS Group submissions

### Unique features:

- User friendly/feasible website-translation of your paper to 50 world's leading languages
- Audio Version of published paper
- Digital articles to share and explore

### Special features:

- 300 Open Access Journals
- 25,000 editorial team
- 21 days rapid review process
- Quality and quick editorial, review and publication processing
- Indexing at PubMed (partial), Scopus, EBSCO, Index Copernicus and Google Scholar etc
- Sharing Option: Social Networking Enabled
- Authors, Reviewers and Editors rewarded with online Scientific Credits
- Better discount for your subsequent articles

Submit your manuscript at: <http://www.omicsonline.org/submit>