

Treatment Challenges for Inflammatory Demyelinating Polyneuropathy in the Setting of Acute Retroviral Syndrome: Case Report and Review of the Literature

David A Lindholm, Tatjana P Calvano, Natascha M Minidis, Thomas J Bayuk, Heather C Yun and Jason F Okulicz*

San Antonio Military Medical Center, Fort Sam Houston, Texas, USA

Abstract

This is a case of a 20-year-old male with acute retroviral syndrome and concurrent acute inflammatory demyelinating polyneuropathy (IDP) progressing to chronic IDP. Whereas the patient followed a relapsing and remitting course prior to the initiation of antiretroviral therapy (ART), he demonstrated gradual and sustained clinical improvement in the ten months of follow-up after ART was combined with chronic corticosteroids and intermittent plasmapheresis. This case presents and addresses multiple challenges for the treatment of IDP in the setting of acute HIV infection to include: timing of initiation and selection of appropriate ART, the potential risk for immune reconstitution inflammatory syndrome, ART initiation in the setting of severe gastroparesis with jejunostomy placement, and the effect of plasmapheresis on the levels of antiretroviral therapy.

Keywords: HIV; AIDP; CIDP; Acute retroviral infection; HIV seroconversion

Introduction

The first case of Guillain-Barré Syndrome (GBS) in the setting of acute retroviral syndrome was reported in 1982 [1]. Since that time, multiple case series of acute and chronic inflammatory demyelinating polyneuropathy (IDP) associated with human immunodeficiency virus (HIV) have been reported. Although the true incidence and prevalence of inflammatory demyelinating polyneuropathies in the setting of HIV are unknown, they are believed to be rare [2]. Nevertheless, acute and chronic IDP result in significant morbidity and mortality in up to 45% of cases in resource-limited settings [1-4].

Treatment of HIV-associated IDP is derived from experience in HIV-negative patients due to the paucity of data in HIV-infected individuals. For this reason, the benefit of early initiation of antiretroviral therapy (ART) is unknown, and there is a potential risk of immune reconstitution inflammatory syndrome (IRIS) after initiation of ART [5,6]. Autonomic dysfunction is common in IDP and can lead to gastric dysmotility, which presents an additional challenge for treatment with ART. This case presents several challenges for the treatment of demyelinating polyneuropathy in the setting of acute HIV, to include considerations for ART initiation, the potential risk for IRIS, balancing the risks and benefits of ART initiation in the setting of severe gastroparesis and jejunostomy placement, and the effect of plasmapheresis on the levels of antiretroviral therapy. These issues will be addressed herein, with significant focus on treatment challenges.

Case Presentation

A 20-year-old male initially diagnosed with mononucleosis syndrome in the setting of a positive heterophile antibody, cervical lymphadenopathy, pharyngitis, and fevers, was admitted to the hospital two months after initial presentation with progressive ascending bilateral lower extremity weakness, significant upper extremity weakness, and areflexia in all four extremities. The patient had associated paresthesias of his feet and hands as well as some progressive numbness on admission. Nerve conduction studies confirmed acute IDP. HIV was suspected and confirmed during his hospitalization. His initial CD4 count was 213 cells/mm³ (CD4% of 11%), and his plasma viral load (VL) was 389,000 copies/mL. This was believed to represent acute retroviral

syndrome since he was HIV-negative on screening two months prior to the onset of his mononucleosis syndrome. Initial cerebrospinal fluid (CSF) studies revealed mild lymphocytic pleocytosis (12 leukocytes/mm³, 86% lymphocytes) and elevated protein (119 mg/dL). Qualitative cytomegalovirus (CMV) IgG and IgM titers were positive, though concurrent CSF viral culture was negative for CMV. Antivirals for CMV were not initiated, and CMV DNA was undetectable in both the serum and CSF seven weeks later.

His polyneuropathy followed a relapsing and remitting course of weakness. He was treated initially with intravenous immunoglobulin (IVIg) and systemic corticosteroids, with sufficient improvement for transfer to an inpatient rehabilitation facility. On his first relapse two weeks after presentation, he was treated with plasmapheresis, again with minor improvement and transfer to inpatient rehabilitation. One month later, he presented with respiratory failure requiring intubation and transfer to our facility. Eventually, the patient required tracheostomy due to persistent weakness of his respiratory muscles resulting in frequent intubations and difficulty liberating from the ventilator. The patient also required placement of a jejunostomy tube due to severe gastroparesis and intractable nausea and vomiting as a part of his autonomic neuropathy. He received five cycles of plasmapheresis with minimal improvement, prompting transition to IVIg, to which he responded well. Based on the duration of symptoms and relapsing nature of his IDP, the patient transitioned from acute to chronic IDP.

ART with raltegravir and tenofovir/emtricitabine was initiated two months after onset of symptoms. Initiation of ART was delayed

***Corresponding author:** Jason F Okulicz, Infectious Disease (MCHE-MDI), San Antonio Military Medical Center, 3551 Roger Brooke Drive, Fort Sam Houston, Texas 78234, USA, Tel: 210-916-5554; Fax: 210-916-0388; E-mail: jason.f.okulicz.mil@mail.mil

Received August 30, 2013; **Accepted** November 12, 2013; **Published** November 17, 2013

Citation: Lindholm DA, Calvano TP, Minidis NM, Bayuk TJ, Yun HC, et al. (2013) Treatment Challenges for Inflammatory Demyelinating Polyneuropathy in the Setting of Acute Retroviral Syndrome: Case Report and Review of the Literature. J AIDS Clin Res 4: 262. doi: [10.4172/2155-6113.1000262](http://dx.doi.org/10.4172/2155-6113.1000262)

Copyright: © 2013 Lindholm DA, et al. This is an open-access article distributed under the terms of the Creative Commons Attribution License, which permits unrestricted use, distribution, and reproduction in any medium, provided the original author and source are credited.

due to the patient's severe gastroparesis and frequent plasmapheresis requirements. The patient's VL was 100,123 copies/mL at ART initiation, and he had an undetectable VL (<20 copies/mL) approximately two weeks after starting ART (Figure 1). While he experienced an additional IDP relapse approximately two weeks after initiating ART, this was attributed to the relapsing-and-remitting course of his polyneuropathy as well as the discontinuation of polyneuropathy therapy following completion of IVIG approximately three weeks earlier. Plasmapheresis and corticosteroids (prednisone 60 mg daily) were re-initiated as part of a chronic treatment course, with ART administered after plasmapheresis sessions.

The patient demonstrated gradual clinical improvement, as evidenced by the removal of his tracheostomy and jejunostomy four months after the onset of illness, as well as the ability to ambulate with assistance six months after the onset of symptoms. On the most recent CSF analysis four months after the onset of polyneuropathy, he displayed resolved pleocytosis (3 cells/mm³) with a persistently elevated CSF protein (437 mg/dL). He continued to receive regular, intermittent plasmapheresis twice-monthly in addition to corticosteroids until 10 months after onset of symptoms. At that time, his VL remained undetectable and CD4 count was 291 cells/mm³ (CD4% 20%). To date, the patient shows continued improvement in strength, though he has some residual weakness and sensory loss as well as mild to moderate dysesthesias of the distal lower extremities. He remained on a low-dose-steroid taper twelve months after symptom onset.

Discussion

HIV infection leads to significant adverse effects on the peripheral and central nervous systems [7]. Peripheral polyneuropathy can occur at the time of seroconversion, most commonly as acute IDP [1,2,8-11]. Histopathologic changes in the brain occur within days

of infection to include significant gray matter abnormalities, as can be seen in acute HIV meningoencephalitis [7]. These changes lead to neurological deficits or decreased neuropsychological functioning, which are often the only symptoms of an acute HIV infection. Peripheral neuropathies are the most frequent neurological disorder associated with HIV infection and are primarily comprised of distal sensory polyneuropathies and antiretroviral toxic neuropathies [8,12]. These are due to immune-mediated injuries produced by HIV infection, opportunistic infections, or direct neurotoxic effects of ART on the peripheral nervous system [8,13]. Although rare, IDP can cause significant morbidity and mortality [1]. Multiple mechanisms have been identified as causative factors in the development of IDP. These mechanisms all involve up-regulation of the immune system, to include T-cell stimulation and subsequent activation, humorally mediated circulating antibodies to myelin antigens, and molecular mimicry, all of which lead to inflammatory infiltration of peripheral nerves and nerve roots and subsequent demyelination [8,13].

The diagnosis of IDP is established based on clinical manifestations of progressive and relapsing motor and sensory dysfunction with generalized hyporeflexia or areflexia or possible autonomic dysfunction, in combination with electrophysiologic studies demonstrating reduced conduction velocity, prolonged distal latencies, temporal dispersion, and/or conduction blocks [2,12,14]. CSF analysis typically reveals elevated protein due to the disruption of the blood-nerve barrier by the action of metalloproteinases. CSF pleocytosis as a predominant feature [15] is characteristic of HIV-associated IDP and distinguishes it from IDP in HIV-uninfected persons, where the CSF typically shows a pattern of albuminocytologic dissociation [2].

Treatment of IDP in the setting of HIV infection is not well known due to the rarity of the condition and lack of supporting evidence in the literature. In addition, starting critically ill patients on ART continues

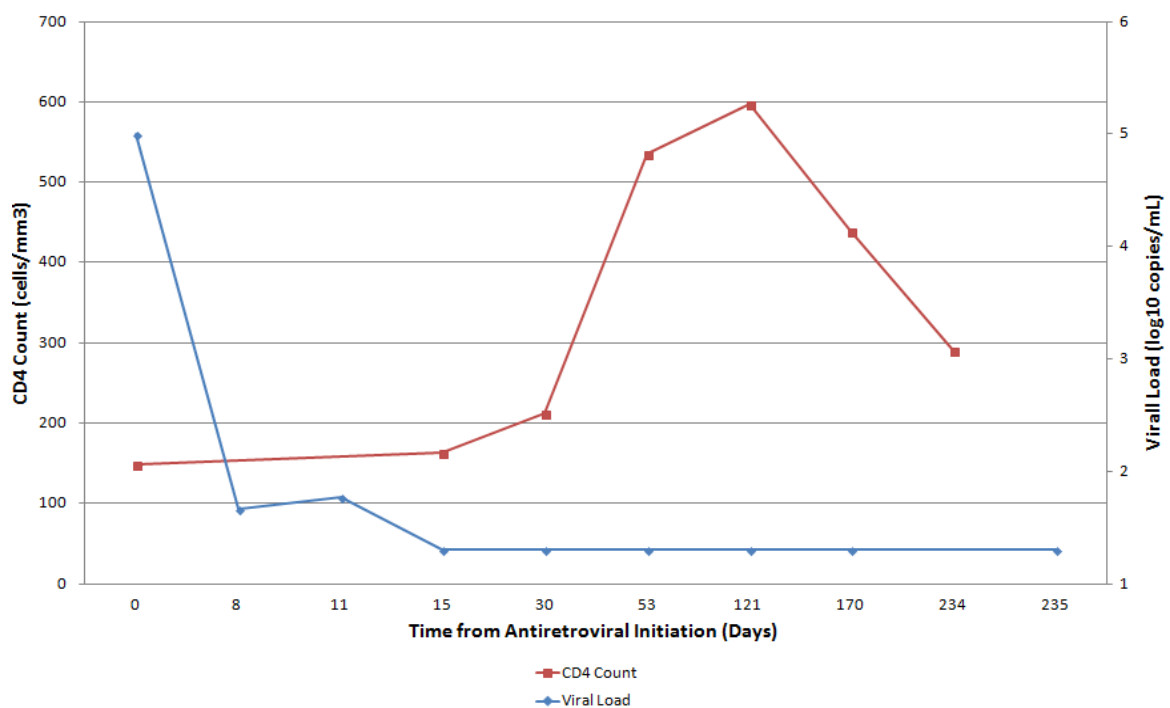


Figure 1: CD4 count and plasma viral load response after initiation of antiretroviral therapy. The viral load decreased below the limit of detection (<20 copies/mL) by treatment day 15.

Reference	Age/Sex	GBS subtype	CD4 (cells/mm ³)	IVIG given	PLEX given	ART given	Outcome
Comblath et al. [11]	22M	CIDP	Not specified	No	Yes	No	Multiple relapses despite PLEX and prednisone; took prednisone with recurrences; died of homicide months after presentation
	31M	CIDP	Not specified	No	No	No	Relapsing course; received prednisone and had resolution of symptoms
	24M	CIDP	Not specified	No	No	No	Relapsing course; recovered without treatment
	45M	CIDP	Not specified	No	Yes	No	PLEX resulted in improvement of neurological symptoms to nearly normal
	37M	CIDP	Not specified	No	No	No	Recovered without treatment
	29F	CIDP	Not specified	No	No	No	Clinical remission with prednisone
	18M	AIDP	Not specified	No	Yes	No	Improvement of symptoms
	27M	AIDP	Not specified	No	Yes	No	Improvement of symptoms
Hagberg et al. [23]	26M	AIDP	Not specified	No	Yes	No	Improvement of symptoms
	56M	AIDP	Not specified	No	No	No	Improvement of symptoms within 4 weeks; able to walk without support at 8 weeks
Vendrell et al. [24]	69M	AIDP	Not specified	No	No	No	On the ventilator for 12 weeks; resolution of weakness in upper extremities and improvement in lower extremities 5 months later
	42M	AIDP	Not specified	No	Yes	No	Improvement of motor weakness by 4 months; moderate quadriparesis 6 months after symptom onset
Conlon [25]	28F	AIDP	Not specified	No	No	No	Died 5 weeks after symptom onset due to ventilator-associated pneumonia
	19F	AIDP	Not specified	No	No	No	Gradual improvement over several weeks, then lost to follow-up
	29F	AIDP	Not specified	No	No	No	Able to walk with support 1 month after symptom onset
Franciotta et al. [26]	25M	AIDP	1276	No	Yes	No	Partially improved neurological symptoms with moderate tetraparesis 5 months after symptom onset
Qureshi et al. [13]	30M	AIDP	5	No	Yes	No	Unable to walk without assistance 1 year after symptom onset
	33M	AIDP	4	Yes	No	No	Strength improved; required a cane to ambulate 1 year after symptom onset
Hassan and Mathew [27]	27M	AIDP	Not specified	Yes	No	No	Complete recovery by week 4 after symptom onset
Bani-Sadr et al. [28]	35M	AIDP	149	No	No	AZT/3TC/RTV/IDV	Complete recovery within 2 months from ART initiation
Brannagan and Zhou [20]	Not specified	AIDP	680	No	No	No	Good recovery with mild dysesthesias
	Not specified	AIDP	300	No	Yes	No	Good recovery; recurrent episodes developed 4 years later, responding to IVIG
	Not specified	AIDP	430	No	Yes	No	Full recovery
	Not specified	AIDP	118	No	Yes	No	Good recovery with dysesthesias
	Not specified	AIDP	800	Yes	No	No	Good recovery – able to ambulate; recurrence 10 weeks later – requires steroids and IVIG
	Not specified	AIDP	685	Yes	No	No	Good recovery; recurrence and paralysis after 9 weeks – requires steroids and IVIG
	Not Specified	AIDP	175	Yes	No	AZT	Died 18 days after symptom onset due to cardiac arrest
	Not specified	AIDP	190	No	Yes	Yes (regimen not specified)	Good recovery with mild residual weakness
Not specified	AIDP	55	Yes	No	Yes (regimen not specified)	Good recovery with mild residual weakness	
Not specified	AIDP	240	No	Yes	Yes (regimen not specified)	Weakness and reflexes recovered; dysesthesias present	
Kumar et al. [29]	21M	AIDP	Not specified	No	Yes	No	Functionally independent at 3-month follow-up; complete resolution at 4-year follow-up
Aggarwal et al. [30]	30M	AIDP	400	No	No	No	Patient left the hospital against medical advice
Gisslén et al. [19]	35M	AIDP	914	Yes	No	D4T/3TC/SQV/NLF	Improvement 3 months after symptom onset; ART stopped; AIDP recurred 2 months later; IVIG and ART started; symptoms resolved in 7 months; ART discontinued and no recurrence
de Castro et al. [31]	38M	AIDP	502	Yes	Yes	AZT/3TC/IDV, then AZT/3TC/RTV, then AZT/3TC/EFV	Two recurrences due to interruption of ART, followed by complete recovery, which was sustained over 3 years when adherent to ART

Wagner and Bromberg [15]	46M	AMAN	150	No	No	Yes (regimen not specified)	Complete recovery 12 months after symptom onset
Hiraga et al. [32]	56M	FS/GBS	24	Yes	No	Yes (regimen not specified)	Complete recovery with continued ART
Sloan et al. [33]	30M	AIDP	408	Yes	No	AZT/3TC/EFV	Complete recovery after 6 months, even after cessation of ART after 6 months
Kumar et al. [34]	38M	AIDP	280	Yes	No	AZT/3TC/EFV	Death due to severe respiratory distress during initial hospital stay
Pontali et al. [35]	56M	AIDP	710	Yes	No	No	Death on day 8 of hospital stay due to cardiac arrest
Schreiber et al. [9]	45F	AIDP	334	Yes	No	No	Complete recovery 5 months after symptom onset
Nishijima et al. [36]	33M	AMAN	334	Yes	No	LPV/RTV/TDF/FTC	Able to walk with a cane after 15 months of rehabilitation
Kume et al. [37]	47M	CIDP	466	No	No	Yes (regimen not specified)	Near complete recovery, with mild dysesthesias and normal NCS 6 months after symptom onset; improvement sustained after 2 years of follow-up
Current case	20M	AIDP	213	Yes	Yes	TDF/FTC/RAL	Recurrent episodes of AIDP, with progression to CIDP; near complete recovery 12 months after symptom onset

*Article in Japanese; data derived from English abstract.

Abbreviations: 3TC: Lamivudine; AIDP: Acute Inflammatory Demyelinating Polyneuropathy; AMAN: Acute Motor Axonal Neuropathy; ART: Antiretroviral Therapy; AZT: Zidovudine; CIDP: Chronic Inflammatory Demyelinating Polyneuropathy; D4T: Didanosine; EFV: Efavirenz; F: Female; FS: Fisher Syndrome; FTC: Emtricitabine; GBS: Guillain-Barré Syndrome; HIV: Human Immunodeficiency Virus; IDP: Inflammatory Demyelinating Polyneuropathy; IDV: Indinavir; IVIG: Intravenous Immunoglobulin; LPV: Lopinavir; M: Male; NCS: Nerve Conduction Study; NLF: Nelfinavir; PLEX: Plasmapheresis; RAL: Raltegravir; RTV: Ritonavir; SQV: Saquinavir; TDF: Tenofovir.

Table 1: Treatment of IDP in ART-naïve patients with HIV infection.

to remain a topic of debate where benefits should clearly outweigh the associated risks [16,17]. IDP is typically treated in the same manner as in HIV-negative patients, with IVIG, plasmapheresis, and/or corticosteroids [2,12,14,18,19]. Rates of recurrence are unknown in the setting of HIV, but overall recurrence rates in GBS are approximately 3% [20]. HIV-associated acute IDP manifests with more frequent and recurrent episodes, a higher likelihood of development of chronic IDP, and a prolonged duration of symptoms [8]. This appears to be associated with acute retroviral syndrome in many cases, and it can be the initial presenting symptom of HIV infection [21]. Clinical findings are similar in HIV-infected patients as in HIV-uninfected patients, except for increased need for ventilator support and mortality among individuals with HIV [3]. The prevalence of HIV in GBS-affected patients is unknown, with the prevalence ranging from zero percent in a Norwegian case series (1980-1992) to approximately 50% in pooled case series from Sub-Saharan Africa. In the African case series, the prevalence of HIV was significantly higher in patients with GBS than it was in the population at large [1,3,4,21]. Multiple challenges occurred during the prolonged course of our patient's illness and are addressed in the following sections.

Role of ART in the treatment of HIV-associated IDP

The US Department of Health and Human Services (DHHS) HIV treatment guidelines recommend ART for all patients with HIV infection [22]. There are cases of complete recovery from IDP after the initiation of ART even in the absence of IVIG and plasmapheresis [9,15]. Reports of recurrent GBS that coincided with periods of HIV viremia due to the interruption of ART suggest that the pathophysiologic mechanisms of HIV-associated GBS are related to the control of HIV viremia. However, there are also published cases with complete recovery of HIV-associated GBS during seroconversion in the absence of ART. Review of pre-ART literature is reflective of multiple cases of GBS associated with acute HIV resulting in complete resolution of symptoms without ART. In some cases, spontaneous recovery occurred despite the absence of any treatment, such as ART, IVIG, plasmapheresis, or steroids. In other cases, however, patients continued to have relapses despite treatment. From the 42 reviewed cases of ART-naïve patients with GBS, the outcomes varied regardless of which treatment was

provided, as demonstrated in Table 1 [9,11,13,15,19,20,23-37]. ART is linked to both the relapse of AIDP upon its discontinuation as well as the cause of AIDP due to drug side-effects and/or IRIS [35]. Our patient did not show sustained, clinical improvement until the treatment of his underlying HIV was combined with chronic corticosteroids and intermittent plasmapheresis. Although the literature regarding the effect of ART on HIV-associated IDP is variable, our case supports the early initiation of ART in the treatment of HIV-associated IDP.

Risk of IRIS with the initiation of ART in the setting of HIV-associated IDP

Among patients with HIV-associated IDP, GBS is rarely attributed to IRIS. However, there are several cases of GBS attributed to IRIS after the initiation of ART has led to a striking increase in the CD4 cell count from a low baseline level [5,6,38]. The exact mechanism of GBS in this setting is unknown, but may be secondary to an aberrant immune response or adverse drug reaction [5,6]. Makela et al. [5] described a case of recurrent GBS six weeks after initiation of ART in an HIV-infected male whose CD4 cell count had increased dramatically from 86 cells/mm³ to 510 cells/mm³. Similarly, Piliero et al. [6] described an HIV-infected patient with AIDS who developed GBS within 26 days after the initiation of a six-drug ART regimen, which led to robust immune reconstitution, with a rise in CD4 cell count from 31 cells/mm³ to 602 cells/mm³. Our patient's episode of relapsing weakness 2 weeks after the initiation of ART was determined not to be a result of IRIS, as this occurred prior to immunologic recovery. Consistent with his pre-ART course, his relapse occurred after several weeks without any IDP treatments. Ultimately, the relapsing-remitting pattern of his course was not altered until long-term co-treatment of both his HIV and IDP was initiated. Although clinicians should be aware of the potential for new or recurrent GBS in the setting of immune reconstitution, its incidence is rare and associated with a dramatic rise from a previously low CD4 cell count.

Role of ART in the setting of severe gastroparesis and post-gastric feeding

Further management challenges presented by our patient included the timing and selection of an effective ART regimen in the setting

of critical illness, IDP, severe gastroparesis, and post-gastric ART administration. Challenges of ART use in the intensive care setting include drug dosage, delivery, interactions, and toxicities, as there are no randomized clinical trials or consensus guidelines to assist in decisions regarding the use of ART in this setting. The absorption of drugs is dependent on multiple factors, including gastrointestinal motility and pH, and is often unpredictable in critically ill patients [39]. The pH ranges from 1 to 2 in the stomach and 7 to 8 in the jejunum, with the increased surface area of the intestinal villi conferring augmented rates of absorption as compared to the stomach [40]. Most antiretroviral medications are only available in oral formulations, with few alternative options to include intravenous formulas (namely, zidovudine), liquids, and powders. Alternatively, for medications without oral solutions, tablets may be crushed and capsules may be opened for use through a feeding tube, although it is unclear whether adequate plasma levels can be achieved in this manner [41]. In general, oral solutions are the preferred method of ART administration through feeding tubes, as the data on crushed tablets or sprinkled capsule contents are even more unreliable in terms of absorption [41]. Currently, there are no pharmacokinetic data available for the evaluation of ART when administered through a jejunostomy tube, which effectively bypasses the acidic gastric environment.

There are case reports in the literature, however, demonstrating successful administration of ART into the jejunum, as measured by detectable plasma levels of drug and a decrease in VL. Two reports demonstrated successful administration of liquid lopinavir/ritonavir into the jejunum [42,43]. A case series of 7 HIV-infected patients undergoing esophagojejunostomies for bariatric surgery showed maintenance of virologic suppression in all but one patient post-surgery [44].

After considering these numerous variables, we considered starting our patient on either a protease-inhibitor-based or an integrase-inhibitor-based regimen in combination with the “backbone” drugs tenofovir and emtricitabine in a fixed-dose combination. Although tenofovir/emtricitabine lacks pharmacokinetic studies performed on crushed versus whole tablets, it does not have an enteric coating or sustained-release formulation that would otherwise preclude it from being crushed. The tablet is known to disintegrate in water or juices and may be consumed immediately after mixing in this manner [45].

The protease inhibitors (PIs) that were primarily considered were ritonavir-boosted lopinavir or darunavir. These PIs are both highly potent, and lopinavir/ritonavir is available in liquid form. However, lopinavir/ritonavir is lipid-soluble, thereby making it more likely to be absorbed in the stomach, particularly in the setting of food, making it a less attractive feature in our patient [46]. Although there is no data regarding darunavir absorption from the jejunum and/or the pharmacokinetic/pharmacodynamic parameters once crushed, the film-coated tablets are not sustained-release and are water-soluble, so they may be successfully crushed and dissolved in water, as was demonstrated in a case report [47,48].

The integrase inhibitor raltegravir is indicated in both treatment-naïve and -experienced patients due to its safety, significant antiviral activity, and tolerability, with few chances of drug interactions compared to other antiretrovirals [49]. Additionally, raltegravir has been shown to cause a rapid decline in the plasma VL up to a 2 log₁₀ reduction within the first two weeks of use, with resultant undetectable VL in a significant number of treated patients [50,51]. Prior studies of raltegravir pharmacokinetics had revealed erratic drug absorption and a high degree of inter- and intra-patient variability in

its pharmacokinetic profile [52]. However, a 2012 study by Cattaneo et al. [52] revealed improved drug absorption and reduced interpatient pharmacokinetic variability in those who received raltegravir by chewing the tablet compared to those who swallowed the intact tablet, a difference attributed to the release of raltegravir from its pharmaceutical formulation. Two case reports have also demonstrated the successful use of raltegravir when administered through non-standard routes: one administered crushed via percutaneous endoscopic gastrostomy tube and the other administered whole through the port of a gastroduodenal tube [53,54].

Considering multiple risks and benefits, we ultimately chose the raltegravir plus tenofovir/emtricitabine regimen for our patient, with a plan to repeat the VL frequently at regular intervals after initiation of therapy. Although the patient did receive his initial doses of both medications crushed via gastrojejunostomy tube, his nausea subsided concurrently and he was able to take the ART orally, mostly crushed, but consumed whole when it was safe to swallow medications.

Role of ART in the setting of plasmapheresis

Data regarding drug removal during plasmapheresis are lacking, and most publications are in the form of case reports describing the effect of plasmapheresis on pharmacologic agents used in overdose attempts [55]. The process of elimination by way of plasmapheresis is complex and takes into account numerous variables, to include plasma volume, intercompartmental equilibration, endogenous clearance, elimination rates, volume of distribution, and the protein binding of the drug [56]. Drug extraction by plasmapheresis cannot be simply or consistently calculated, nor can it be categorized into definitive or absolute terms. At a minimum, clinicians should avoid proceeding with plasmapheresis until the drug in question has had adequate time to complete its extravascular distribution [55]. In the same manner, ART is best administered immediately after a plasmapheresis session in order to minimize the potential of drug removal in preparation for subsequent plasmapheresis and to maximize drug exposure [57]. For these reasons, once-daily ART regimens are most compatible with plasmapheresis. At the time that our patient was initiated on ART, he had already completed courses of both IVIG and plasmapheresis, allowing us to dose a twice-daily ART regimen. The patient did require further plasmapheresis sessions as an outpatient, but at a frequency of twice per week, again allowing us to continue his twice-daily ART regimen.

Conclusion

IDP in the setting of HIV infection is associated with significant morbidity and mortality. Clinical outcomes in HIV-associated IDP are variable, even after ART initiation. The limited number of reported cases and the complexity of IDP in the setting of HIV lead to many challenges in the management of these conditions. Despite these challenges, this case demonstrates the successful co-treatment of HIV and IDP with ART and a multitude of interventions for IDP, including long-term steroids and intermittent plasmapheresis.

References

- Schleicher GK, Black A, Mochan A, Richards GA (2003) Effect of human immunodeficiency virus on intensive care unit outcome of patients with Guillain-Barré syndrome. *Crit Care Med* 31: 1848-1850.
- Verma A (2001) Epidemiology and clinical features of HIV-1 associated neuropathies. *J Peripher Nerv Syst* 6: 8-13.
- Melaku Z, Zenebe G, Bekele A (2005) Guillain-Barré syndrome in Ethiopian patients. *Ethiop Med J* 43: 21-26.

4. Howlett WP, Vedeler CA, Nyland H, Aarli JA (1996) Guillain-Barré syndrome in northern Tanzania: a comparison of epidemiological and clinical findings with western Norway. *Acta Neurol Scand* 93: 44-49.
5. Makela P, Howe L, Glover S, Ferguson I, Pinto A, et al. (2002) Recurrent Guillain-Barre syndrome as a complication of immune reconstitution in HIV. *J Infect* 44: 47-49.
6. Piliro PJ, Fish DG, Preston S, Cunningham D, Kinchelov T, et al. (2003) Guillain-Barré syndrome associated with immune reconstitution. *Clin Infect Dis* 36: e111-114.
7. Ragin AB, Du H, Ochs R, Wu Y, Sammet CL, et al. (2012) Structural brain alterations can be detected early in HIV infection. *Neurology* 79: 2328-2334.
8. Pardo CA, McArthur JC, Griffin JW (2001) HIV neuropathy: insights in the pathology of HIV peripheral nerve disease. *J Peripher Nerv Syst* 6: 21-27.
9. Schreiber AL, Norbury JW, De Sousa EA (2011) Functional recovery of untreated human immunodeficiency virus-associated Guillain-Barré syndrome: a case report. *Ann Phys Rehabil Med* 54: 519-524.
10. Lipkin WI, Parry G, Kiprov D, Abrams D (1985) Inflammatory neuropathy in homosexual men with lymphadenopathy. *Neurology* 35: 1479-1483.
11. Comblath DR, McArthur JC, Kennedy PG, Witte AS, Griffin JW (1987) Inflammatory demyelinating peripheral neuropathies associated with human T-cell lymphotropic virus type III infection. *Ann Neurol* 21: 32-40.
12. Ferrari S, Vento S, Monaco S, Cavallaro T, Cainelli F, et al. (2006) Human immunodeficiency virus-associated peripheral neuropathies. *Mayo Clin Proc* 81: 213-219.
13. Qureshi AI, Cook AA, Mishu HP, Krendel DA (1997) Guillain-Barré syndrome in immunocompromised patients: a report of three patients and review of the literature. *Muscle Nerve* 20: 1002-1007.
14. Robinson-Papp J, Simpson DM (2009) Neuromuscular diseases associated with HIV-1 infection. *Muscle Nerve* 40: 1043-1053.
15. Wagner JC, Bromberg MB (2007) HIV infection presenting with motor axonal variant of Guillain-Barré Syndrome. *J Clin Neuromuscul Dis* 9: 303-305.
16. Meybeck A, Lecomte L, Valette M, Van Grunderbeek N, Boussekey N, et al. (2012) Should highly active antiretroviral therapy be prescribed in critically ill HIV-infected patients during the ICU stay? A retrospective cohort study. *AIDS Res Ther* 9: 27.
17. Soni N, Pozniak A (2001) Continuing HIV therapy in the ICU. *Crit Care* 5: 247-248.
18. Wulff EA, Wang AK, Simpson DM (2000) HIV-associated peripheral neuropathy: epidemiology, pathophysiology and treatment. *Drugs* 59: 1251-1260.
19. Gisslén M, Fredman P, Fuchs D, Lekman A, Rosengren L (2005) Temporarily controlled HIV-1 replication after intravenous immunoglobulin treatment of Guillain-Barré syndrome. *Scand J Infect Dis* 37: 877-881.
20. Brannagan TH 3rd, Zhou Y (2003) HIV-associated Guillain-Barré syndrome. *J Neurol Sci* 208: 39-42.
21. Thornton CA, Latif AS, Emmanuel JC (1991) Guillain-Barré syndrome associated with human immunodeficiency virus infection in Zimbabwe. *Neurology* 41: 812-815.
22. AIDS info (2013) Guidelines for the use of antiretroviral agents in HIV-1-infected adults and adolescents. Panel on Antiretroviral Guidelines for Adults and Adolescents, Department of Health and Human Services.
23. Hagberg L, Malmvall BE, Svennerholm L, Alestig K, Norrans G (1986) Guillain-Barré syndrome as an early manifestation of HIV central nervous system infection. *Scand J Infect Dis* 18: 591-592.
24. Vendrell J, Heredia C, Pujol M, Vidal J, Blesa R, et al. (1987) Guillain-Barré syndrome associated with seroconversion for anti-HTLV-III. *Neurology* 37: 544.
25. Conlon CP (1989) HIV infection presenting as Guillain-Barre syndrome in Lusaka, Zambia. *Trans R Soc Trop Med Hyg* 83: 109.
26. Franciotta DM, Brustia R, Minoli L, Bono G, Ceroni M, et al. (1992) Acute Guillain-Barré syndrome associated with asymptomatic HIV infection. *Acta Neurol (Napoli)* 14: 66-70.
27. Hassan KM, Mathew I (2000) Guillain Barre' syndrome--in an HIV seropositive subject. *J Assoc Physicians India* 48: 1214.
28. Bani-Sadr F, Neuville S, Crassard I, Guihot A, Molina JM (2002) Acute Guillain-Barré syndrome during the chronic phase of HIV infection and dramatic improvement under highly active antiretroviral therapy. *AIDS* 16: 1562.
29. Kumar S, Alexander M, Markandeyulu V, Gnanamuthu C (2003) Guillain-Barre syndrome presenting in the anti-HIV seroconversion period. *Neurol India* 51: 559.
30. Aggarwal HK, Chakrabarti D, Nand N, Sonia, Bharti K, et al (2005) HIV infection presenting as Guillain-Barré syndrome. *JACM* 6: 341-342.
31. de Castro G, Bastos PG, Martinez R, de Castro Figueiredo JF (2006) Episodes of Guillain-Barré syndrome associated with the acute phase of HIV-1 infection and with recurrence of viremia. *Arq Neuropsiquiatr* 64: 606-608.
32. Hiraga A, Kuwabara S, Nakamura A, Yuki N, Hattori T, et al. (2007) Fisher/Guillain-Barré overlap syndrome in advanced AIDS. *J Neurol Sci* 258: 148-150.
33. Sloan DJ, Nicolson A, Miller AR, Beeching NJ, Beadsworth MB (2008) Human immunodeficiency virus seroconversion presenting with acute inflammatory demyelinating polyneuropathy: a case report. *J Med Case Rep* 2: 370.
34. Kumar N, Pandey K, Das VN, Sinha PK, Topno RK, et al. (2008) HIV infection, visceral leishmaniasis and Guillain-Barré syndrome in the same patient: a case report. *Ann Trop Med Parasitol* 102: 185-188.
35. Pontali E, Feasi M, Crisalli MP, Cassola G (2011) Guillain-Barré Syndrome with Fatal Outcome during HIV-1-Seroconversion: A Case Report. *Case Rep Infect Dis* 2011: 972096.
36. Nishijima T, Tsukada K, Takeuchi S, Chiba A, Honda M, et al. (2011) Antiretroviral therapy for treatment-naïve chronic HIV-1 infection with an axonal variant of Guillain-Barré syndrome positive for anti-ganglioside antibody: a case report. *Intern Med* 50: 2427-2429.
37. Kume K, Ikeda K, Kamada M, Touge T, Deguchi K, et al. (2013) Successful treatment of HIV-associated chronic inflammatory demyelinating polyneuropathy by early initiation of highly active anti-retroviral therapy. *Rinsho Shinkeigaku* 53: 362-366.
38. Puthanakit T, Oberdorfer P, Akarathum N, Wannarit P, Sirisanthana T, et al. (2006) Immune reconstitution syndrome after highly active antiretroviral therapy in human immunodeficiency virus-infected Thai children. *Pediatr Infect Dis J* 25: 53-58.
39. Schanker LS, Shore PA, Brodie BB, Hogben CA (1957) Absorption of drugs from the stomach. I. The rat. *J Pharmacol Exp Ther* 120: 528-539.
40. Miller AD, Smith KM (2006) Medication and nutrient administration considerations after bariatric surgery. *Am J Health Syst Pharm* 63: 1852-1857.
41. Huang L, Quartin A, Jones D, Havlir DV (2006) Intensive care of patients with HIV infection. *N Engl J Med* 355: 173-181.
42. Boffito M, Lucchini A, Maiello A, Dal Conte I, Hoggard PG, et al. (2003) Lopinavir/ritonavir absorption in a gastrectomized patient. *AIDS* 17: 136-137.
43. Kamimura M, Watanabe K, Kobayakawa M, Mihara F, Edamoto Y, et al. (2009) Successful absorption of antiretroviral drugs after gastrojejunal bypass surgery following failure of therapy through a jejunal tube. *Intern Med* 48: 1103-1104.
44. Selke H, Norris S, Osterholzer D, Fife KH, DeRose B, et al. (2010) Bariatric surgery outcomes in HIV-infected subjects: a case series. *AIDS Patient Care STDS* 24: 545-550.
45. Truvada (emtricitabine/tenofovir disoproxil fumarate) [package insert]. Foster City, CA.
46. Kaletra (lopinavir/ritonavir) [package insert]. North Chicago, IL.
47. Prezista (darunavir) [package insert]. Titusville, NJ.
48. Scholten S, Mauruschat S, Hindermann S, Ranneberg B (2010) Administration of darunavir tablets in patients with difficulties in swallowing - two case reports. *J Int AIDS Soc* 13: p114.
49. Eron JJ, Young B, Cooper DA, Youle M, Dejesus E, et al. (2010) Switch to a raltegravir-based regimen versus continuation of a lopinavir/ritonavir-based regimen in stable HIV-infected patients with suppressed viraemia (SWITCHMRK 1 and 2): two multicentre, double-blind, randomised controlled trials. *Lancet* 375: 396-407.
50. Markowitz M, Morales-Ramirez JO, Nguyen BY, Kovacs CM, Steigbigel RT, et al. (2006) Antiretroviral activity, pharmacokinetics, and tolerability of MK-0518, a novel inhibitor of HIV-1 integrase, dosed as monotherapy for 10 days in treatment-naïve HIV-1 infected individuals. *J Acquir Immune Defic Syndr* 43: 509-515.

51. Markowitz M, Nguyen BY, Gotuzzo E, Mendo F, Ratanasuwan W, et al. (2007) Rapid and durable antiretroviral effect of the HIV-1 integrase inhibitor raltegravir as part of combination therapy in treatment-naive patients with HIV-1 infection: results of a 48-week controlled study. *J Acquir Immune Defic Syndr* 46: 125-133.
52. Cattaneo D, Baldelli S, Cerea M, Landonio S, Meraviglia P, et al. (2012) Comparison of the in vivo pharmacokinetics and in vitro dissolution of raltegravir in HIV patients receiving the drug by swallowing or by chewing. *Antimicrob Agents Chemother* 56: 6132-6136.
53. Sandkovsky U, Swindells S, Moore R, Acosta EP, Fletcher CV (2012) Acceptable plasma concentrations of raltegravir and etravirine when administered by gastrostomy tube in a patient with advanced multidrug-resistant human immunodeficiency virus infection. *Pharmacotherapy* 32: 142-147.
54. Taegtmeier AB, Müller V, Kovari H, Kullak-Ublick GA, Corti N (2011) Effect of continuous venovenous hemodiafiltration on darunavir and raltegravir exposure after administration via a gastroduodenal tube. *AIDS* 25: 1339-1341.
55. Ibrahim RB, Liu C, Cronin SM, Murphy BC, Cha R, et al. (2007) Drug removal by plasmapheresis: an evidence-based review. *Pharmacotherapy* 27: 1529-1549.
56. Nenov VD, Marinov P, Sabeva J, Nenov DS (2003) Current applications of plasmapheresis in clinical toxicology. *Nephrol Dial Transplant* 18: v56-58.
57. Hart D, Sayer R, Miller R, Edwards S, Kelly A, et al. (2011) Human immunodeficiency virus associated thrombotic thrombocytopenic purpura favourable outcome with plasma exchange and prompt initiation of highly active antiretroviral therapy. *Br J Haematol* 153: 515-519.

Citation: Lindholm DA, Calvano TP, Minidis NM, Bayuk TJ, Yun HC, et al. (2013) Treatment Challenges for Inflammatory Demyelinating Polyneuropathy in the Setting of Acute Retroviral Syndrome: Case Report and Review of the Literature. *J AIDS Clin Res* 4: 262. doi: [10.4172/2155-6113.1000262](https://doi.org/10.4172/2155-6113.1000262)

Submit your next manuscript and get advantages of OMICS Group submissions

Unique features:

- User friendly/feasible website-translation of your paper to 50 world's leading languages
- Audio Version of published paper
- Digital articles to share and explore

Special features:

- 300 Open Access Journals
- 25,000 editorial team
- 21 days rapid review process
- Quality and quick editorial, review and publication processing
- Indexing at PubMed (partial), Scopus, EBSCO, Index Copernicus and Google Scholar etc
- Sharing Option: Social Networking Enabled
- Authors, Reviewers and Editors rewarded with online Scientific Credits
- Better discount for your subsequent articles

Submit your manuscript at: <http://www.omicsonline.org/submission>