

Voluminous Gastric Stromal Tumors: Place of Surgery about 5 Cases at the Dakar Cancer Institute

Sidy Ka*, Marc Kamwanga T, Adja Coumba D, Jaafar T and Ahmadou D

Surgical Oncologist, Joliot Curie Institute, Dakar, Senegal

*Corresponding author: Sidy Ka, Surgical Oncologist, Joliot Curie Institute, Dakar, Senegal, Tel: +221338250530; E-mail: sidy.ka@ucad.edu.sn

Received date: 8 June, 2017; Accepted date: 20 June, 2017; Published date: 30 June, 2017

Copyright: © 2017 Ka S, et al. This is an open-access article distributed under the terms of the Creative Commons Attribution License, which permits unrestricted use, distribution, and reproduction in any medium, provided the original author and source are credited.

Abstract

Objectives: To describe the surgical and prognostic aspects of voluminous gastric stromal tumors at Joliot Curie Cancer Institute.

Methods: This was a retrospective study of patients with voluminous stromal tumors from January 2010 to December 2015. Patients had a bulky gastric mass at the clinical examination and CT and had positive CD117 marker. Local stage and extension was evaluated and surgical treatment studied. Prognosis was also analyzed according to surgery and adjuvant treatment.

Results: Five large GISTs were found. Most are women with a mean age of 39. The tumor was palpable in all patients. Other symptoms are pain and vomiting. Gastroscopy found a burgeoning tumor in 4 patients with external compression in 1 patient. Biopsy showed stromal tumor with fusiform cells in 3 patients and epithelioid cells in 2 patients. CD117 and CD34 were positive in all patients. Abdominal and thoracic CT showed a sus mesocolic mass voluminous with multi visceral involvement without distant metastasis. Surgery consisted in all cases of total gastrectomy extended to the spleen, the tail of the pancreas, the colon and the liver. One patient died of postoperative peritonitis at day five. There was none other immediate post-operative complications. All patients received adjuvant treatment with Imatinib. After a 23-month follow-up, 1 patient experience important sarcopenia while 1 patient recurred to the liver and brain with resistance to Imatinib and second line Sunitinib and died.

Conclusion: voluminous gastric GIST in Africa is characterized by young age and involvement of sus mesocolic organs. Surgery with Imatinib as first line adjuvant treatment showed good results.

Keywords: GIST; Gastric; Multi visceral; Involvement; Surgery; Imatinib; Prognosis

Introduction

Gastrointestinal Stromal Tumors (GIST) are related to the group of soft tissue sarcomas, of which they constitute about 20% [1]. The prognosis of GIST improved with the advent of Imatinib. The best treatment remains surgery which represents the only potentially curative treatment [2]. Their most frequent primary sites are the stomach (about 60% of cases) and the small intestine (25%) [3]. The main discussion in the literature is about laparoscopic versus open approaches. The size of GIST in the stomach can be very large, involve other organs. In this cases surgery and the following treatments represent a great challenge. The objective of this work was to describe the therapeutic and prognostic aspects of voluminous gastric stromal tumors at Joliot Curie Cancer Institute.

Methods

This was a retrospective study of patients with voluminous gastric stromal tumors from January 2010 to December 2015. Patients had a bulky gastric mass at the clinical examination and CT and had positive CD117 marker. Local stage and extension was evaluated and surgical treatment studied. Prognosis was also analysed according to surgery and adjuvant treatment.

Results

Five large GISTs were found. They were 3 women and 2 men. The mean age was 39.5 with extremes of 21 and 56. Pain was found in 3 patients. Vomiting occurred in 2 patients. Mass was palpable in all patients. Gastroscopy found a burgeoning tumor in 4 patients with external compression in 1 patient. Biopsy showed stromal tumor with fusiform cells in 3 patients and epithelioid cells in 2 patients. CD117 and CD34 were positive in all patients. Abdominal and thoracic CT showed a sus mesocolic mass with large necrosis suggestive of GIST with multi visceral invasion in 2 cases (Figure 1).

There was no distant metastasis. Pancreatic tail, spleen and transverse colon invasion were seen in 1 patient while invasion of the left liver occurred in 1 patient. Surgical exploration showed involvement of the gastric curvatures (Figure 2).

Surgery consisted in all cases of total gastrectomy. It was extended to the spleen, the tail of the pancreas, the transverse colon in 1 patient and to the left liver in 1 other patient (Figure 3).

One patient died of postoperative peritonitis at day five. There was none other immediate post-operative complications. All patients received adjuvant treatment with Imatinib. Evaluation of quality of life showed in 3 patients acceptable behaviour and in 1 patient important sarcopenia. After a 23-month follow-up, one patient recurred to the liver and brain with resistance to Imatinib and second line Sunitinib and died.

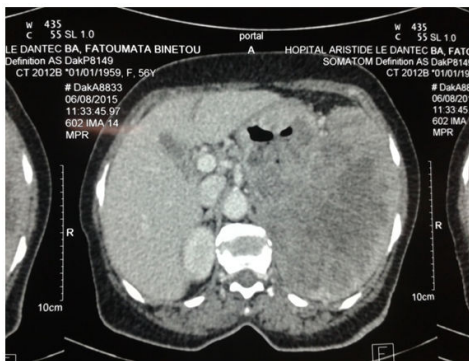


Figure 1: Computed tomography of a large GIST with central necrosis.

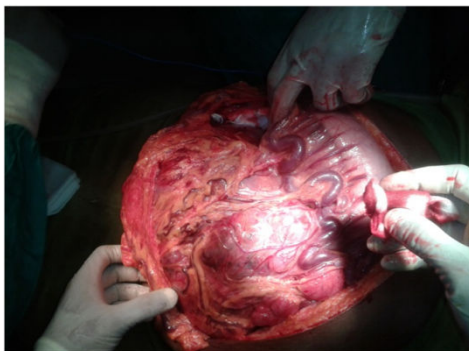


Figure 2: Operative view of a large GIST.

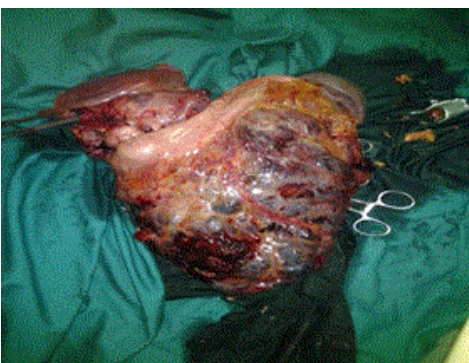

Figure 3: Surgery part of a large GIST with spleen and liver involvement.

Discussion

GIST account for 5.6% of gastric tumors at Joliot Curie Cancer Institute in Dakar.

The exact incidence of GIST is still difficult to evaluate due to recent changes in their definition [3]. These tumors account for less than 3% of gastrointestinal tumors [4]. The incidence seems to be the same in

the other african series [5,6]. Male predominance is not really confirmed [7,8]. Stromal tumors can occur at any age but are infrequent before 40 years [9-11]. GISTs are often asymptomatic. They may be revealed by nonspecific symptoms such as occult digestive bleeding, pain or abdominal mass [12-14]. Bleeding and pain are the most frequent symptoms. In african series, mass is the first symptom [7,15]. The frequency of stromal lesions under the gastric epithelial during gastroscopy makes it necessary to use echo endoscopy. It makes it possible to distinguish the GIST from an extrinsic compression [16,17]. The mean size after CT is 10 cm [18]. This examination allows to evoke the diagnosis in more than 80% of the cases and to predict the prognosis. The pejorative prognosis arguments for survival are a diameter greater than 11 cm, an irregular surface, blurred borders, invasion of the wall of the digestive segment or mesentery, heterogeneous contrast, hepatic metastases and peritoneal dissemination [19]. Surgical treatment is the cornerstone of the treatment. The quality of the surgical procedure (R0 versus R1) has a prognostic impact. The best surgical results are obtained after complete surgery without tumor split with a five-year survival of 50% [20]. If surgery is macroscopically incomplete or in case of preoperative rupture of the tumor, overall survival at five years drops to less than 10%. The resectability rate of non-metastatic primary tumors oscillates between 60 and 90% [21]. Although the conventional route is preferred over laparoscopy, the feasibility of laparoscopic resection of GIST has been demonstrated for tumors of less than 5 cm with an advantage in terms of operative time, hospital stay, blood transfusion [22,23]. Tumor size plays an important role in resectability and choice of approach. Locally advanced GIST are less frequent in the literature. The quality of the resection partially compensates for the disadvantage of size [24]. Immediate post-operative complications are related to the type of surgery. In case of resection of numerous organs, complications such as infections, fistulas are more frequent [11]. Delayed complications are characterised by post gastrectomy insufficiency such as dumping syndrome and particularly sarcopenia [25]. It is related to the extension of the underlying neoplasm and the gastrectomy [26]. The efficacy of Imatinib as adjuvant treatment and in metastatic situation is established [27]. Neo-adjuvant treatment is not recommended outside of a clinical trial. Its effectiveness remains to be defined in the residual lesions as well as in surgery for metastatic lesions [28]. The resectability of the tumor is an important prognostic factor. The overall survival at twelve months and sixty months is 80% and 45% respectively [29,30].

Conclusion

GISTs of the stomach are characterized by younger age and large sizes at diagnosis in Africa. Factors of poor prognosis are closely related to tumor size. The surgical treatment is essential for prognosis often consists of multi-visceral excision. Resection is difficult to complete. The use of tyrosine kinase inhibitors and more recently of the anti-angiogenic agents improves the results of the surgery in adjuvant and metastatic situation. Their efficacy is doubtful in case of multiple metastases.

References

1. Ducimetiere F, Lurkin A, Ranchere-Vince D, Decouvelaere AV, Isaac S, et al. (2010) Incidence rate, epidemiology of sarcoma and molecular biology. Preliminary results from EMS study in the Rhone-Alpes region. *Bull Cancer* 97: 629-641.
2. Lehnert T (1998) Gastrointestinal sarcoma (GIST): A review of surgical management. *Ann Chir gynacol* 87: 297-305.

3. Hove MG, Kasiya W (2000) Gastro-intestinal stromal tumors: a six year Zimbabwean experience. Cellular differentiation with immunocytochemistry. *Centr Afr Med J* 46: 314-318.
4. Gervaz P, Huber O, Morel P (2009) Surgical management of gastrointestinal stromal tumors. *Br J Surg* 96: 567-578.
5. Abdulkareem FB, Rotimi O, Banjo AA (2009) Immunophenotyping mesenchymal tumours in Lagos, Nigeria. *West Afr J Med* 28: 358-363.
6. Heinrich MC, Rubin BP, Longley BJ, Fletcher JA (2002) Biology and genetic aspects of gastrointestinal stromal tumors: KIT activation and cytogenetic alterations. *Hum Pathol* 33: 484-495.
7. Aparicio T, Yacoub M, Karila-Cohen P (2004) Gastric carcinoma: epidemiology, diagnosis and treatment. *EMC-Chirurgie* 1: 47-66.
8. Tryggvason G, Gislason HG, Magnusson MK, Jónasson JG (2005) Gastrointestinal stromal tumors in Iceland, 1990-2003: the icelandic GIST study, a population-based incidence and pathologic risk stratification study. *Int J Cancer* 117: 289-293.
9. Coindre JM, Emile FJ, Monges G, Ranchère-Vince D, Scaozec JY (2005) Tumeurs stromales gastrointestinales: définition, caractéristiques histologiques, immunohistochimiques et génétiques, stratégie diagnostique. *Ann. Pathol* 25: 358-385.
10. Wu TJ, Lee LY, Yeh CN, Wu PY, Chao TC, et al. (2006) Surgical treatment and prognostic analysis for gastrointestinal stromal tumors (GISTs) of the small intestine: before the era of imatinib mesylate. *BMC Gastroenterol* 6: 29.
11. Gluzman MI, Kashchenko VA, Karachun AM, Orlova RV, Nakatis IA, et al. (2017) Technical success and short-term results of surgical treatment of gastrointestinal stromal tumors: an experience of three centers 2: 56.
12. Chan KT, Chan CW, Chow WH, Kwan WK, Kong CK, et al. (2006) Gastrointestinal stromal tumors in cohort on chinese patients in Hong kong. *World J Gastroenterol* 12: 2223-2228.
13. Clere F, Carola E, Halimi C, Gramont AD, S Bonvalot, et al. (2002) Actualités sur les tumeurs stromales gastro-intestinales : a partir de sept observations de tumeurs malignes. *Rev Méd Interne* 23: 499-507.
14. Yamada Y, Kida M, Sakugushi T (1992) A study on myogenic of the gastrointestinal tract by endoscopic ultrasonographic. *Digestive Endo* 4: 396-408.
15. Hong X, Choi H, Loyer EM (2006) Gastrointestinal stromal tumor: role of CT in diagnosis and in response evaluation and surveillance after treatment with imatinib. *Radiographics* 26: 481-95.
16. Blay J, Bonvalot S, Casali P, Choi H, Debiec-Richter M, et al. (2005) Consensus meeting for the management of gastrointestinal stromal tumors. Report of the GIST Consensus Conference of 20-21 March 2004, under the auspices of ESMO. *Ann Oncol* 16: 566-578.
17. Landi B (2008) Endoscopic approach to GIST. *J chir* 145: 654-657.
18. Miettinen M, Makhlof H, Sobin LH, Lasota J (2006) Gastrointestinal stromal tumors of the jejunum and ileum: a clinicopathologic, immunohistochemical, and molecular genetic study of 906 cases before imatinib with long-term follow-up. *Am J Surg Pathol* 30: 477-489.
19. Lehnert T (1998) Gastrointestinal sarcoma (GIST): a review of surgical management. *Ann Chir gynacol* 87: 297-305.
20. Goha B, Gohc Y, Engc A, Chanc W, Chow PKH, et al. (2015) Outcome after laparoscopic versus open wedge resection for suspected gastric gastrointestinal stromal tumors: A matched-pair case-control study. *European Journal of Surgical Oncology* 905-910.
21. Rossi S, Miceli R, Messerini L, Bearzi I, Mazzoleni G, et al. (2011) Natural history of imatinibnaive GISTs: a retrospective analysis of 929 cases with long-term follow-up and development of a survival nomogram based on mitotic index and size as continuous variables. *Am J Surg Pathol* 35: 1646-1656.
22. Rubin B, Fletcher J (2000) Molecular insights into the histogenesis and pathogenesis of gastrointestinal stromal tumors. *International Journal of Surgical Pathology* 8: 5-10.
23. Boni L, Benevento A, Dionigi G, Rovera F, Dionigi R, et al. (2005) Surgical resection for gastrointestinal stromal tumors (GIST): experience on 25 patients. *World Journal of Surgical Oncology* 30: 78-89.
24. Demetri G, von Mehren M, Blanke C, Van den Abbeele AD, Eisenberg B, et al. (2002) Efficacy and safety of imatinib mesylate in advanced gastrointestinal stromal tumors. *N Engl J Med* 347: 472-480.
25. Aahlin EK, Tranø G, Johns N, Horn A, Søreide JA (2017) Health-Related Quality of Life, Cachexia and Overall Survival After Major Upper Abdominal Surgery: A Prospective Cohort Study. *Scand J Surg* 106: 40-46.
26. Aahlin EK, Tranø G, Johns N, Horn A, Søreide JA (2015) Risk factors, complications and survival after upper abdominal surgery: a prospective cohort study. *BMC Surg* 15: 83.
27. Da Dalt D, Rizzetto D, Pastorelli D, Farinati F, Bertorelle R, et al. (2010) Survival and prognostic factors analysis in surgically resected gastrointestinal stromal tumor (GIST) patients. An Interdisciplinary GIST Group Study (432). *Journal de Chirurgie Viscérale* 21: 147-127.
28. Bonvalot S (2005) Mise au point Traitement chirurgical des GIST à l'heure du Glivec. *Annales de chirurgie* 130: 144-151.
29. Heinrich, Rubin BP, Longley BJ, Fletcher JA (2002) Biology and genetic aspects of gastrointestinal stromal tumors: KIT activation and cytogenetic alterations. *Hum Pathol* 33: 484-495.
30. McGrath P, Neifeld J, Lawrence J, Kay S, Horsley JS, et al. (1987) Gastrointestinal sarcomas. Analysis of prognostic factors. *Ann Surg* 206: 706-710