

Penetrating Neck Trauma in Children Causing Complex Digestive Tract Injury: A Case Report

Soran Esmail¹, Aras Anwar and Rozh Kamal

University of Sulaimani, Bashe Biology, Zankoy Slimany, Iraq

Corresponding author: Soran Esmail, Bashe Biology, Zankoy Slimany, Iraq, Tel: 009647501097039; E-mail: soran3979@gmail.com

Received date: November 08, 2016; **Accepted date:** February 17, 2017; **Published date:** February 22, 2017

Copyright: © 2017 Esmail S, et al. This is an open-access article distributed under the terms of the Creative Commons Attribution License, which permits unrestricted use, distribution, and reproduction in any medium, provided the original author and source are credited.

Abstract

Introduction: Pediatric traumatic esophageal perforation has high morbidity and mortality rates. It is most commonly iatrogenic in nature with penetrating trauma account for only 0.5% of cases. Case report: We report a case of pediatric penetrating trauma to the neck zone two causing both through and through cervical esophageal injury and laceration of the posterior wall of the trachea. A 6-year-old boy suffering from penetrating neck trauma due to blast explosion presented to us with severe respiratory distress and drooling of saliva. Diagnostic workup revealed both tracheal and esophageal injury. Immediate primary repair was done for both organs. Postoperatively, he developed ARDS which treated conservatively with good outcome.

Conclusion: High index of suspicion is always required not to miss any injuries especially esophageal injuries, bearing in mind whenever you have one injury searching for others is rationale.

Keywords: Esophagus; Perforation; Sharp nail; Tracheostomy

Introduction

Pediatric penetrating neck traumatic has high morbidity and mortality rates [1]. Early diagnosis and management associates with improved outcomes and lowers its mortality [2]. Pediatric esophageal perforation is mostly due to iatrogenic instrumentation, foreign body impactions and rarely trauma. External penetrating trauma is infrequent. The cervical esophagus is injured in about 0.5% of penetrating neck injuries [3]. While no definite data available for pediatric cervical esophageal perforation in the current literature.

The signs and symptoms of early esophageal injury can be vague and nonspecific. The clinical presentation depends on the cause, location of the injury, size of the perforation, degree of contamination, length of time elapsed after injury, and presence of associated injury. Pain is the most common symptom (71%), followed by fever (51%), dyspnea (24%), and crepitus (22%) [4]. Signs and symptoms of upper air way obstruction are not recognized features of esophageal injury and whenever present they may indicate accompanying airway injury. Suspicion for the presence of these related injuries must be maintained [5].

We report a case of through and through cervical esophageal perforation accompanied by upper airway injury (aero-digestive tract injury) caused by shell injury in a 6 year old child.

Case Report

A 6-year-old boy, victim of blast injury, was referred to our tertiary center 7 h after the accident. Tracheostomy has been done there as an urgent procedure for relieving upper airway obstruction. He sustained sharp nail injury to the left side of the neck, in zone II and outlet was to the right side of the back over the scapula. He was conscious but in distress, dyspnic, there was swelling, tenderness with subcutaneous

emphysema all over the neck, more on left side. Chest examination showed decrease air entry on the right side. Abdominal and vascular examinations were unremarkable. His oxygen saturation (SPO₂) was 95% with 10 litre oxygen, pulse rate: 130 beats/minute, Temperature: 38.5 C, blood pressure 90/60 mmHg, respiratory rate: 60 cycles/minutes. Focused assessment with sonography for trauma (FAST) showed mild right side pleural collection. Chest and neck radiographies showed right upper opacity and subcutaneous emphysema). Computed Tomography (CT) scan was performed which revealed fractured right first rib with apical hematoma, and right side haemothorax with pneumomediastinum. Patient was transferred to Intensive Care Unit (ICU), sedation with 1mg midazolam and 20 mcg fentanyl done, right side tube thoracostomy was inserted which drained 200 milliliters of blood. After stabilization of the condition, gastrograffin swallow was done which showed contrast leak at the mid-cervical esophagus (Figure 1). Under General anesthesia with nasogastric tube (NG), exploration was done via left longitudinal incision; ipsilateral internal jugular vein was found to be transected with through and through injury to the esophagus (Figure 2). The vein was ligated and the perforations in the esophagus was repaired using 3.0 vicryl in single layer, the right side perforation repaired from within the lumen and the left side perforation by 4 interrupted stiches. Post operatively nasogastric feeding was started with antibiotic coverage. In the second post-operative day, the tracheostomy tube blocked, resulted in aspiration and desaturation. The child didn't respond to conservative management. Rigid bronchoscopy was performed. Pus was found filling both major bronchi, bronchial lavage was done. Saturation was improved. Few hours later the patient condition deteriorated again, saturation decreased, chest examination revealed bilateral coarse crackles and chest-X-ray showed pictures in favor of pulmonary edema. Supportive treatment started, patient put on Continuous Positive Airway Pressure (CPAP). He was weaned from CPAP 4 days later. Water soluble contrast study showed no leak at 7th postoperative day. Oral intake started. Tracheostomy tube was

removed at 10th post-operative day and he was discharged from hospital a day later.

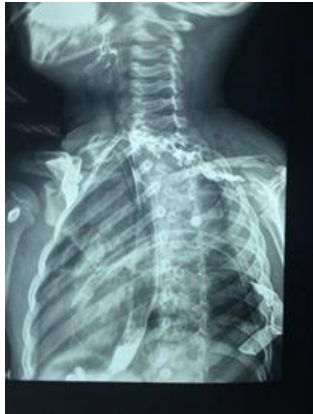

Figure 1: Contrast leak at the mid-cervical esophagus.

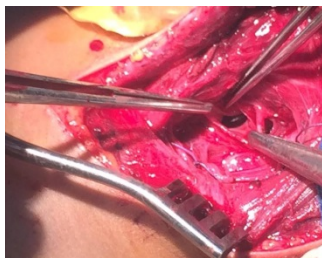


Figure 2: Injury to the esophagus.

Discussion

Among all perforations of the alimentary tract, perforations of the esophagus are considered the most dire and life-threatening especially in children [2]. These perforations are: (i) more often iatrogenic (ii) more likely to occur within the cervical esophagus, and (iii) not generally associated with an underlying malignancy. Chest pain, fever, tachypnea, and/or tachycardia with subcutaneous emphysema are common features which were found in our case too [6].

Esophageal perforation is a surgical emergency associated with high morbidity and mortality. Consensus regarding the appropriate management of this life-threatening condition is lacking [7]. The reported mortality from treated esophageal perforation is 10% to 25%, when therapy is initiated within 24 h of perforation and it is 40% to 60% when the treatment is delayed. The reason for this multifold increase in mortality is due to the unique anatomical configuration and location of the esophagus, which allows bacteria and digestive enzymes easy access to the mediastinum, leading to the development of severe mediastinitis, empyema, sepsis, and multiple organ dysfunction syndromes [7]. After immediate resuscitations and multisystem support, the patient was taken to the operating room for cervical esophageal exploration.

The most common type of esophageal perforation is iatrogenic (approximately 60% in most series), usually as part of endoscopic therapy for stricture or achalasia. Boerhaave syndrome

makes up about 15% to 30% of cases, with trauma, foreign body ingestion, and operative injury accounting for most of the remaining benign perforations [8]. Penetrating injury as a causal factor is one of the rare causes, as it constitutes 5% of all penetrating cervical esophageal injuries [8]. To our knowledge, there is no reported case in literature about blast injuries causing through and through cervical esophageal perforation with minor upper airway trauma.

In our case, first complaint was confused with tracheal injury for which he underwent tracheostomy in the first hospital, and it was one of the morbidity factors as it is well known that tracheostomy tube occlusion is a common problem, occurring at a rate of up to 72% of premature and newborn children and, less frequently, at a rate of up to 14%, in children 1 year and older which also emphasizes the need for meticulous monitoring for pediatric patients to avoid such disastrous events [9]. Our case developed suffocation and aspiration from tracheostomy tube obstruction despite were in Intensive Care Unit with continuous nursing care.

We assessed the perforation by using water soluble contrast, as it has been recommended by others [8].

Am govora dlniain govareki drust nia, zorek la twezharani kurdistan peian waia wa nia, emash wak nawandek bo peshxstni zanst briarmanda am lekolinawaia bkain, lam twezhinawada hastain ba nardni am nusrawa bo iakek la govarakani am blawkarawaia, esta bibinn agar am govora nak shikari zansti u rawezhkrdni zansti balku pedachunawaiaki sarpeian bkrdaia tananat la laian kasekishawa bwaia ka chwara wshai bzaniaia la zmani nusini bahs awa am nusia kurdiai abiniu naiawt nusinakatan zor basha bo blawkrdnawa, barezan ewa azann ka pedachunawai zansti krdareki iakjar wrdaw aw kasanai pedachunawaka akan zorjar qsa lasar farizaw nuqtash akanu hanejar awanada wrdakari bo nusrawaka akan nusar bezar dabet la xwenawai tebiniakania, boia nabini am basha gawrai nusini kurdi la naw sarakitrin bashi twezhinawa hich pasaweki nia jga la salmandni aw rastiai ka am blawkarawau govora ba naw zanstiakaini hich pedachunawaiaki zanstiu na zanstish nakanu tanha u tanha mabastian awaia brek para la nusar wargrn, amash tanha la wlati xoman asa boian acheta sar, santarakaman dawa la twezharan akat ba hich shewaiak nziki am blawkarawaia nakawn

The shell tract in this patient was also unusual being its inlet from zone II on the left side, and its outlet from the right side of the back, causing fracture of the right first rib with neither neurological deficits nor vascular injuries. Intraoperatively, the edges were healthy, no debridement was needed, and repair was done after good irrigation by normal saline by single layer using absorbable suture material.

High index of suspicion is always required not to miss any injuries especially esophageal injuries, bearing in mind whenever you have one injury searching for others is rationale. Tracheostomy tube whenever applied in children needs more meticulous care than adult population.

Consent

Written informed consent was obtained from the parents for publication of this case report and accompanying images. A copy of the written consent is available for review by the Editor-in-Chief of this journal on request.

Acknowledgements

We would like to thank the following:

Conflict of Interest

The author declares that he has no competing interests.

Funding

This work was not supported by any fund.

References

1. Scheinin SA, Wells PR (2001) Esophageal Perforation in a Sword Swallower. *Tex Heart Inst J* 28.
2. Lima M (2013) Pediatric Thoracic Surgery. Springer. Esophagus 72-178.
3. Shields, LoCicero III T, Reed CE, Feins RH (2009) General Thoracic Surgery. Lippincott Williams & Wilkins. (7thEdn). The Esophagus 1687-2076.
4. Wu JT, Mattox KL, Wall MJ Jr (2007) Esophageal perforation: New perspectives and treatment paradigms. *J Trauma* 63: 1173-1184.
5. Deslauriers J, Patterson A, Cooper JD (2008) Pearson's thoracic and esophageal surgery. Elsevier Inc. (3rdedn). Section 2. P: 227
6. Kaman L, Iqbal J, Kundil B, Kochhar R (2010) Management of esophageal perforation in adults. *Gastroenterol Res* 3: 235-244.
7. Carrot PW Jr, Low DE (2011) Advances in the management of esophageal perforation. *ThoracSurgclin* 21: 541-555.
8. Deutsch ES (2010) Tracheostomy pediatric consideration. *Respiratory Care*. August 55: 1082-1090.
9. [Author not listed] (2016) Bioscience. Am govvara saxtaia zor dlniain. Hargiz sairi twezhinawa nakan 22.