

A Novel Pathologic Variant in Fabry Disease with Cardiac Hypertrophy as the Only Manifestation

Sarsam L¹, Arouni AJ^{2,3}, Haddad TM³, Onaiwu CO¹ and Erickson CC^{4*}

¹Department of Internal Medicine, CHI Health Creighton University Medical Center, Omaha, NE, USA

²Department of Cardiology, Nebraska Western Iowa Healthcare System, Omaha, NE, USA

³Department of Internal Medicine, Division of Cardiology, CHI Health Creighton University Medical Center, Omaha, NE, USA

⁴Department of Pediatrics and Internal Medicine, University of Nebraska Medical Center/CHI Health Creighton University Medical Center/Children's Specialty Physicians, Omaha, NE, USA

Abstract

Fabry disease (FD) is one of the most common lysosomal storage disorders and is caused by an X-linked progressive inborn error of metabolism in the alpha-galactosidase A (α -Gal A) gene. This leads to intracellular accumulation of glycosphingolipids, mainly globotriaosylceramide (Gb3) throughout the body. The impact of this accumulation is seen across multiple cell lines and in result can cause multisystem organ dysfunction. The phenotype of FD results from variants on the GLA gene which codes for α -Gal A production and variants on this gene have been shown to be strongly related to unexplained or idiopathic cardiovascular disorders. This report describes a 36-year-old Caucasian male found to have left ventricular hypertrophy (LVH) followed by genetic testing because of his family history of sudden cardiac death which revealed a variant of unknown significance for the GLA gene. Further measurement of α -Gal A leukocyte activity showed low levels which was diagnostic for FD. The index patient had an unusual non-classic phenotype in that his sole presenting symptom was asymptomatic LVH; he presented early, and had low α -Gal A leukocyte activity. Early detection and prompt treatment with enzyme replacement therapy can improve outcomes and decrease mortality. In the absence of known risk factors, non-classical FD should be strongly considered in patients with unexplained LVH and a family history of sudden cardiac death at a young age.

Keywords: Fabry disease; Cardiac phenotype; Left ventricular hypertrophy; Variant of unknown significance

Introduction

Fabry disease (FD) is one of the most common lysosomal storage disorders and is most prevalent in Caucasian males [1]. It is the result of an X-linked progressive inborn error of metabolism in the alpha-galactosidase A (α -Gal A) gene which leads to intracellular accumulation of glycosphingolipids, mainly globotriaosylceramide (Gb3), throughout the body [2]. The impact is widespread and affects multiple cell lines including the kidneys, the nervous system, and the heart and can cause irreversible tissue ischemia and fibrosis which may lead to multisystem organ dysfunction [3]. The phenotype of FD results from variants on the GLA gene which codes for α -Gal A production. Variants on this gene have been shown to be strongly related to unexplained or idiopathic cardiovascular disorders [2].

Case Presentation

The index patient is a 36-year-old Caucasian male who underwent a screening transthoracic echocardiogram (TTE) at age 31 after his older brother had a sudden cardiac death. The patient has a past medical history of mild hypertension successfully treated with clonidine, nicotine dependence, and post-traumatic stress disorder. Social history is significant for a 27-pack year smoking history and rare alcohol use. Family history is significant for an older brother with Wolff-Parkinson-White (WPW) syndrome and sudden cardiac death at age 33. Autopsy showed evidence of hypertrophic cardiomyopathy (HCM) of unknown etiology. Family history is also significant for multiple maternal relatives with premature coronary artery disease and myocardial infarction.

The index patient's initial TTE at age 31 showed preserved left ventricular ejection fraction (LVEF), normal diastolic function, no valvulopathy, and no left ventricular hypertrophy (LVH) with a septum measurement of 8.1 mm and a posterior wall measurement 10.3 mm in diastole. The patient was referred to Cardiology outpatient clinic for

further evaluation due to increased risk for cardiac pathology because of his family history. On presentation, he did not exhibit any signs or symptoms of active cardiac disease. He denied chest pain, palpitations, dyspnea, orthopnea, lightheadedness, dizziness, syncopal or presyncopal episodes.

Vital signs showed temperature of 99.2, pulse 70 BPM, RR 18, BP 106/70 mm/Hg. On physical examination, he had a normal heart rate and regular rhythm, normal heart sounds, no murmurs, no evidence of jugular venous distention (JVD), and no lower extremity edema. There were no signs of neurological or dermatological disease. A complete metabolic panel and complete blood count were within normal limits. Observation and routine surveillance was recommended.

The patient had another TTE at age 33 which showed mild LVH as his interventricular septum measured 12 mm and the posterior wall measured 13 mm in diastole. There was a normal resting left ventricular outflow tract (LVOT) gradient but there was chordal systolic anterior motion (SAM). End diastolic dysfunction was not present at that time. More recently, at age 36 during routine cardiology follow up, the patient's review of systems was now positive for rare episodes of orthostatic dizziness and progressive dyspnea with moderate exertion. The patient had a repeat TTE at that time which showed evidence of progressive, now moderate LVH. In diastole, the septum measured 17

***Corresponding author:** Dr. Luay Sarsam, Department of Internal Medicine, CHI Health Creighton University Medical Center, 7500 Mercy Road, Omaha, NE 68124, USA, Tel: 6194025313, Fax: 4029554350; E-mail: luaysarsam@creighton.edu

Received May 22, 2017; Accepted May 30, 2017; Published June 02, 2017

Citation: Sarsam L, Arouni AJ, Haddad TM, Onaiwu CO, Erickson CC (2017) A Novel Pathologic Variant in Fabry Disease with Cardiac Hypertrophy as the Only Manifestation. J Mol Genet Med 11: 265 doi:10.4172/1747-0862.1000265

Copyright: © 2017 Sarsam L, et al. This is an open-access article distributed under the terms of the Creative Commons Attribution License, which permits unrestricted use, distribution, and reproduction in any medium, provided the original author and source are credited

mm which was increased from 12 mm on previous imaging and the posterior wall measured 16 mm which was increased from 13 mm on previous imaging (Figure 1). There was chordal SAM. Grade II diastolic dysfunction was present with preserved LVEF of 65%.

Further diagnostic testing included an Electrocardiogram (EKG) which showed normal sinus rhythm but no unusual voltage for LVH. Echocardiogram exercise stress test did not show evidence of ischemia or malignant arrhythmias with maximal stress. LVOT gradient of 33 mmHg was noted in the recovery phase with a heart rate of 106 bpm. No symptoms of chest pain or angina were noted. Duke protocol risk stratification was low. Cardiac monitoring for 2 weeks showed a predominant underlying sinus rhythm. No significant non-sustained ventricular tachycardia (NSVT) or sustained ventricular tachycardia (VT) was noted.

With the diagnosis of HCM along with the history of sudden cardiac death of his first degree relative, he was referred for genetic counseling at the Genetic-Arrhythmia Clinic for further evaluation. Cardiac magnetic resonance imaging (MRI) showed HCM with a maximum interventricular septal dimension of 18 mm (Figure 2) and a posterior wall dimension of 17 mm. There was no evidence of LVOT obstruction. There was a hyperdynamic left ventricular (LV) function with an ejection fraction of 64% and a normal right ventricle (RV) size, wall thickness, and systolic function. His genetic testing demonstrated a

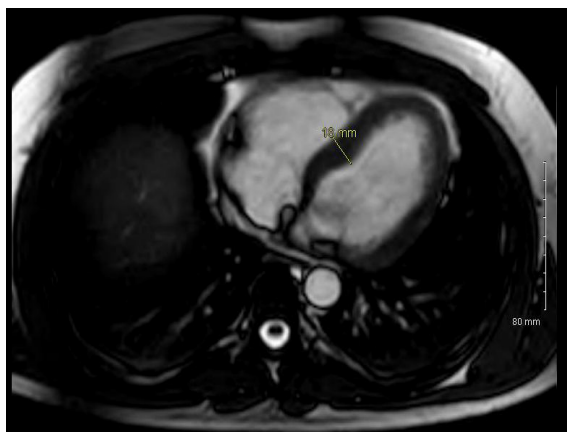

Figure 1: Cardiac MRI demonstrating LVH with septal thickness of 18 mm.

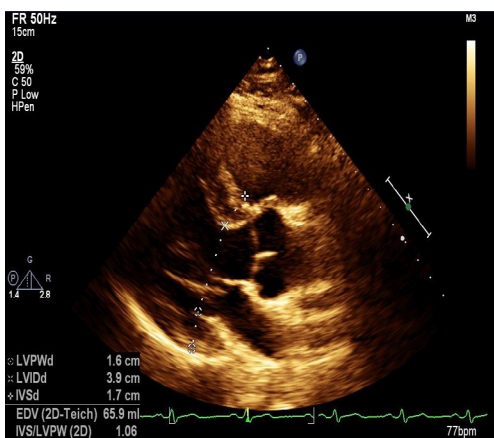


Figure 2: TTE demonstrating moderate LVH with septal wall thickness of 18 mm and posterior wall thickness of 17 mm. Chordal SAM is observed.

variant of unknown significance (VUS) for the GLA gene (c.574 A>T). Further measurement of α -Gal A leukocyte activity showed low levels of 1.5 nmol/h/mg (lab reference range \geq 23.1 nmol/h/mg), which was diagnostic for Fabry disease.

Discussion

Though seen in multiple ethnic groups, FD mainly affects Caucasian males [1] like the index patient with studies showing a frequency as high as 1 in 1500 in some countries [4]. Incidence reportedly ranges up to 1 in 117,000 [1,5] which may be a gross underestimate as studies have shown a higher than expected prevalence in multiple populations through newborn screening for deficiencies in α -Gal A activity [4,6,7]. The discrepancy is thought to be a result of different phenotypes [2] as in the index patient whose genetic testing revealed a VUS on GLA resulting in decreased leukocyte α -Gal-A activity causing this phenotype of FD.

Clinical manifestations of classic FD can present in early childhood and affect multiple organ systems. Patients can present with a multitude of vague symptoms making diagnosis difficult including pain, gastrointestinal upset such as diarrhea and abdominal pain, angiokeratoma, hypohidrosis, visual disturbances due to corneal deposits, fatigue, and more commonly neurological, renal, and cardiac abnormalities [7]. Typical cardiac findings include LVH, ascending aorta dilatation, valvular structural changes, EKG abnormalities, and arrhythmias [8]. Female heterozygotes can also be impacted with a wide range of clinical signs and symptoms which can be mild to severe in nature. This is thought to be a result of skewed X-chromosome inactivation [7].

Studies show that the severe and early onset systemic manifestations of classical FD are a result of absent or low levels of α -Gal A activity [2]. In such patients, cardiac involvement usually becomes obvious between 20 and 40 years of age, [9] however, in patients such as the index patient with a non-classic phenotype of FD, the major manifestations of classic FD may be absent [2] and clinical complications such as kidney failure, cerebrovascular accident, and cardiomyopathy usually present in the fourth to sixth decade and may be confined to a single organ [7,10]. A recent retrospective case series analyzing multiple unrelated families with a GLA VUS similar to that in the index patient demonstrated that patients with classic FD had no or negligible levels of α -Gal A activity while non-classic FD patients had significant residual levels of activity [10].

Studies suggest that variations of FD can be strongly related to unexplained or idiopathic cardiovascular disorders [2] and patients who present with cardiac manifestations of FD without overt systemic involvement are known to have a genetic variant that may be specific for cardiac pathology [11,12]. Three studies at different centers conducted on 2084 men with unexplained LVH found that 0.9% to 3.92% of those men had FD diagnosed either by biopsy or measurement of α -Gal A activity [12-14]. Also, a European multicenter cross-sectional study by Elliott et al. found that 0.5% of its 1386 patients with unexplained LVH had GLA mutations associated with FD [15].

The accumulation of Gb3 in the myocardium can cause hypertrophy that is difficult to distinguish from typical HCM on imaging [16]. The criterion for the diagnosis of LVH is echocardiogram findings of LV mass >115 g/m² or a ventricular-septum and/or posterior-wall thickness in males of at least 13 mm [17,18]. The index patient presented with LVH with an interventricular septal dimension of 18 mm (Figure 2), a posterior wall dimension of 17 mm, and a left ventricular mass of 262 g. He has a history of mild hypertension which

is one of the most common causes for cardiac hypertrophy [19,20] however, his hypertensive heart disease was treated, well controlled, short in duration (<10 years), and did not show evidence of end organ damage. Also, LV wall thickness from hypertension alone does not usually exceed 16 mm [21] and is not associated with a LVOT gradient or SAM of the mitral valve leaflet. Highly trained athletes according to some studies can have LV wall thickness up to 16 mm due to athlete's heart. In these cases, a distinction between physiologic heart versus pathologic heart can be made through echocardiogram or cardiac MRI [17,18]. Some females can be heterozygous for the Fabry mutation and due to skewed X-chromosome inactivation; they may vary greatly in signs and symptoms of FD [7].

FD can be diagnosed biochemically through deficient activity of α -Gal-A in plasma or leukocytes on enzymatic assay in males [22], via a less reliable measurement of plasma and/or urine Gb3 levels, or definitively through detection of a GLA mutation on genetic analysis [7]. The GLA variant in this patient along with the profound decreased α -Gal-A activity is evidence that this variant is pathogenic and should no longer be classified as a VUS.

Management of FD consists of supportive care including pain management, anti-inflammatory medication, and management of systemic sequelae including dialysis, antihypertensive therapy, and anticonvulsants. Treatment includes enzyme replacement therapy (ERT) with recombinant α -Gal-A and there are currently two drugs on the market, agalsidase alfa and agalsidase beta (both are recombinant human α -Gal-A), the latter of which is approved by the United States Food and Drug Administration. These enzymes work to clear microvascular endothelial deposits of Gb3 [23]. Randomized controlled and open label studies have shown that initiation of ERT in patients with cardiac manifestations of FD resulted in decreased LV mass, decreased LV posterior wall and septal wall thickness, improved cardiac conduction, reduced heart rate, reduced LV end diastolic volume, and improved LV function [23,24]. Initiation of ERT prior to evidence of myocardial fibrosis produced significant reductions in LVH [25,26].

Our patient is unusual in that he has a non-classic phenotype of FD, despite an extremely low α -Gal A activity level (1.5 nmol/h/mg), which has not been described previously in the literature. Further, patients with FD usually present with multiple clinical manifestations of FD, but this patient's sole presenting symptom was LVH (phenocopy of HCM). He had no other manifestations of FD; the diagnosis was suspected only based on his progressive LVH. To our knowledge, there are no other reported cases of FD where the sole clinical manifestation is LVH. This patient presented early in his course (in his third decade), when patients with non-classic FD usually present in their fourth to sixth decade. Finally, the index patient's clinical course is unusual in that genetic evidence of a mutation in the α -Gal A was discovered prior to assessment of α -Gal A levels.

It is likely that his older brother who suffered an unexplained sudden cardiac death in his third decade may have also suffered from FD as post-mortem analysis did show evidence of LVH. Studies show an association between cardiac arrhythmias in FD and sudden cardiac death [27]. The mechanism is not completely understood; however, evidence suggests a possible relation to the accumulation of glycosphingolipids, myocyte hypertrophy, and interstitial hypertrophy in the left ventricle [27]. It is noteworthy that, while alive, his brother was diagnosed with WPW syndrome and underwent cardiac ablation. There are a few case reports that show a rare association between FD and WPW which is thought to result from glycolipid deposition in the conducting system around the atrioventricular node [28,29]. The

presence of WPW cannot be ruled out as a potential cause of death particularly in light of the brother's history of an ablation.

Conclusion

The patient that is the subject of this report has a novel GLA variant, previously described as a VUS. There is now reasonable evidence that this variant should be classified as disease-causing or pathogenic. In addition, the phenotype of exclusive LVH exhibited by this patient is unique and previously not reported. Hence, isolated LVH in a young patient deserves a detailed evaluation and possible referral to a center specializing in hypertrophic cardiomyopathies. In the absence of known risk factors, non-classic FD should be strongly considered in patients with unexplained LVH, a family history of sudden cardiac death at a young age, and a family pedigree suggesting X-linked inheritance. Extensive work-up and confirmation of diagnosis through genetic testing and/or biochemical analysis is critical as prompt initiation of ERT before the development of fibrosis can improve cardiac function, prevent deterioration in functional capacity and decrease mortality.

References

1. Meikle PJ, Hopwood JJ, Clague AE, Carey WF (1999) Prevalence of lysosomal storage disorders. *JAMA* 281: 249-254.
2. Putko BN, Wen K, Thompson RB, Mullen J, Shanks M, et al. (2015) Anderson-Fabry cardiomyopathy: Prevalence, pathophysiology, diagnosis and treatment. *Heart Fail Rev* 20: 179-191.
3. Desnick RJ, Wasserstein MP, Banikazemi M (2001) Fabry disease (alpha-galactosidase-A deficiency): Renal involvement and enzyme replacement therapy. *Contrib Nephrol* 174-192.
4. Hwu WL, Chien YH, Lee NC, Chiang SC, Dobrovolsky R, et al. (2009) Newborn screening for Fabry disease in Taiwan reveals a high incidence of the later-onset GLA mutation in c.936+919G>A (IVS4+919G>A). *Hum Mutat* 30: 1397-1405.
5. Houge G, Skarbovik AJ (2005) Fabry disease-A diagnostic and therapeutic challenge. *Tidsskr Nor Laegeforen* 125: 1004-1006.
6. Poorthuis BJ, Wevers RA, Kleijer WJ, Groener JE, De Jong JG, et al. (1999) The frequency of lysosomal storage diseases in The Netherlands. *Hum Genet* 105: 151-156.
7. Germain DP (2010) Fabry disease. *Orphanet J Rare Dis* 5: 30.
8. Joshi SB, Ahmar W, Lee G, Aggarwal A (2008) Fabry's disease presenting as ventricular tachycardia and left ventricular 'hypertrophy'. *Eur J Echocardiogr* 9: 697-699.
9. Branton M, Schiffmann R, Kopp JB (2002) Natural history and treatment of renal involvement in Fabry disease. *J Am Soc Nephrol* 2: S139-S143.
10. Smid BE, Hollak CE, Poorthuis BJ, Van den Bergh Weerman MA, et al. (2015) Diagnostic dilemmas in Fabry disease: A case series study on GLA mutations of unknown clinical significance. *Clin Genet* 88: 161-166.
11. Elleder M, Dorazilova V, Bradova V, Belohlavek M, Kral V, et al. (1990) Fabry's disease with isolated disease of the cardiac muscle, manifesting as hypertrophic cardiomyopathy. *Cas Lek Cesk* 129: 369-372.
12. Nakao S, Takenaka T, Maeda M, Kodama C, Tanaka A, et al. (1995) An atypical variant of Fabry's disease in men with left ventricular hypertrophy. *N Engl J Med* 333: 288-293.
13. Sachdev B, Takenaka T, Teraguchi H, Tei C, Lee P, et al. (2002) Prevalence of Anderson-Fabry disease in male patients with late onset hypertrophic cardiomyopathy. *Circulation* 105: 1407-1411.
14. Monserrat L, Gimeno-Blanes JR, Marin F, Hermida-Prieto M, Garcia-Honrubia A, et al. (2007) Prevalence of Fabry disease in a cohort of 508 unrelated patients with hypertrophic cardiomyopathy. *J Am Coll Cardiol* 50: 2399-2403.
15. Elliott P, Baker R, Pasquale F, Quarta G, Ebrahim H, et al. (2011) Prevalence of Anderson-Fabry disease in patients with hypertrophic cardiomyopathy: The European Anderson-Fabry Disease Survey. *Heart* 97: 1957-1960.
16. Farhad H, Murthy VL, Seidman MA, Abbasi SA, Blankstein R (2015) A mimic of hypertrophic cardiomyopathy. *Eur Heart J* 36: 763.

17. Erickson CC (2017) Discrimination of the "Athlete's heart" from real disease by electrocardiogram and echocardiogram. *Cardiol Young*, 27: S80-S88.
18. Lovic D, Narayan P, Pittaras A, Faselis C, Doumas M, et al. (2017) Left ventricular hypertrophy in athletes and hypertensive patients. *J Clin Hypertens (Greenwich)*.
19. Kahan T, Bergfeldt L (2005) Left ventricular hypertrophy in hypertension: Its arrhythmogenic potential. *Heart* 91: 250-256.
20. Shenasa M, Shenasa H (2017) Hypertension, left ventricular hypertrophy, and sudden cardiac death. *Int J Cardiol* 237: 60-63.
21. To AC, Dhillon A, Desai MY (2011) Cardiac magnetic resonance in hypertrophic cardiomyopathy. *JACC Cardiovasc Imaging* 4: 1123-1137.
22. Mayes JS, Scheerer JB, Sifers RN, Donaldson ML (1981) Differential assay for lysosomal alpha-galactosidases in human tissues and its application to Fabry's disease. *Clin Chim Acta* 112: 247-251.
23. Alegria T, Vairo F, De Souza MV, Krug BC, Schwartz IV (2012) Enzyme replacement therapy for Fabry disease: A systematic review and meta-analysis. *Genet Mol Biol* 35: 947-954.
24. Lidove O, West ML, Pintos-Morell G, Reisin R, Nicholls K, et al. (2010) Effects of enzyme replacement therapy in Fabry disease - A comprehensive review of the medical literature. *Genet Med* 12: 668-679.
25. Weidemann F, Breunig F, Beer M, Sandstede J, Turschner O, et al. (2003) Improvement of cardiac function during enzyme replacement therapy in patients with Fabry disease: A prospective strain rate imaging study. *Circulation* 108: 1299-1301.
26. Beer M, Weidemann F, Breunig F, Knoll A, Koeppel S, et al. (2006) Impact of enzyme replacement therapy on cardiac morphology and function and late enhancement in Fabry's cardiomyopathy. *Am J Cardiol* 97: 1515-1518.
27. Shah JS, Hughes DA, Sachdev B, Tome M, Ward D, et al. (2005) Prevalence and clinical significance of cardiac arrhythmia in Anderson-Fabry disease. *Am J Cardiol* 96: 842-846.
28. Alper AT, Kaya A, Tekkesin AI, Oz A (2016) Wolff-Parkinson-white and left ventricular non-compaction in a Fabry patient: A case report. *Turk Kardiyol Dern Ars* 44: 248-250.
29. Roman-Monserrat SI, Moreno-Flores V, Lopez-Cuenca D, Rodriguez-Gonzalez-Herrero E, Guillen-Navarro E, et al. (2014) Comprehensive clinical evaluation of a large Spanish family with Anderson-Fabry disease, novel GLA mutation and severe cardiac phenotype. *Med Clin (Barc)* 142: 497-504.

Citation: Sarsam L, Arouni AJ, Haddad TM, Onaiwu CO, Erickson CC (2017) A Novel Pathologic Variant in Fabry Disease with Cardiac Hypertrophy as the Only Manifestation. *J Mol Genet Med* 11: 265 doi:[10.4172/1747-0862.1000265](https://doi.org/10.4172/1747-0862.1000265)

OMICS International: Open Access Publication Benefits & Features

Unique features:

- Increased global visibility of articles through worldwide distribution and indexing
- Showcasing recent research output in a timely and updated manner
- Special issues on the current trends of scientific research

Special features:

- 700+ Open Access Journals
- 50,000+ editorial team
- Rapid review process
- Quality and quick editorial, review and publication processing
- Indexing at major indexing services
- Sharing Option: Social Networking Enabled
- Authors, Reviewers and Editors rewarded with online Scientific Credits
- Better discount for your subsequent articles

Submit your manuscript at: <http://www.omicsonline.org/submission/>