

## Percutaneous Salvage Surgery for Weil Metatarsal Osteotomies

Conesa X\*, Ustes X, Parals F, Ribau MA, Via-Dufresne O and Novell J

Department of Orthopedic Surgery and Traumatology Hospital Municipal de Badalona, Barcelona, Spain

### Abstract

Metatarsalgia is one of the most common reasons for orthopedic surgery consultations. Open surgery using Weil osteotomy techniques is widely accepted to treat metatarsalgia when orthopedic management fails. However, the presence of the osteosynthesis screw and the distal position of the osteotomy significantly complicates salvage procedures. We present a series of patients in whom persistent postoperative metatarsalgia was resolved by percutaneous osteotomies.

### Introduction

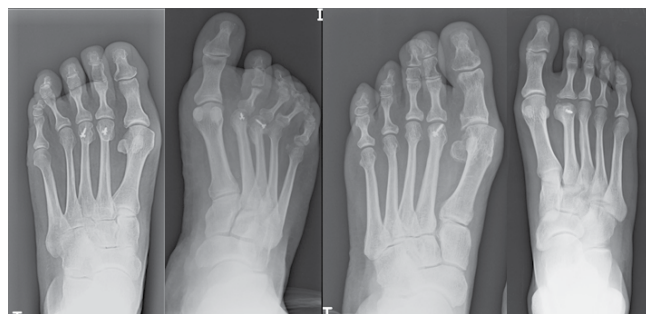Metatarsalgia, a term that refers to pain developing in the area across the plantar forefoot, is a common reason for consulting in orthopedic surgery. This condition is usually associated with abnormal pressure-loading at the heads of the metatarsals and is accompanied by plantar hyperkeratosis [1]

The cause may be of systemic origin (eg, rheumatologic, metabolic or neuropathic diseases) or related to a traumatic/iatrogenic source, with the most common being a mechanical disruption, such as metatarsal drop or excessive length. Metatarsal drop produces selective pain during the midstance phase of the gait cycle (second rocker) and leads to formation of a callosity under the metatarsal head. When one or more of the metatarsals are longer than the other, pain is produced during the push-off phase (third rocker), and in general, the callosities are more distal and less focally located [2].

Orthopedic treatment, including a change in the type of footwear and the use of padded inserts, is the first therapeutic option, with surgery being indicated when these conservative measures fail. At present, the most widely used surgical treatment is open distal metatarsal osteotomy using a Weil technique with screw fixation. When surgical treatment does not yield satisfactory results, the presence of the synthesis screw and the distal position of the osteotomy significantly complicate salvage surgery [1-3].

### Case Reports

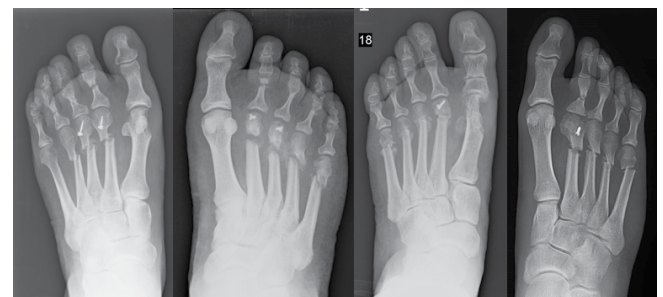We present four clinical cases of patients surgically treated using Weil osteotomies, in whom the symptoms of metatarsalgia persisted. Two patients had received osteotomies of the second and third rays for isolated metatarsalgia, the third patient had undergone osteotomy of the second ray in the context of hallus valgus, and the last patient had undergone osteotomy of the second metatarsal to treat Freiberg disease



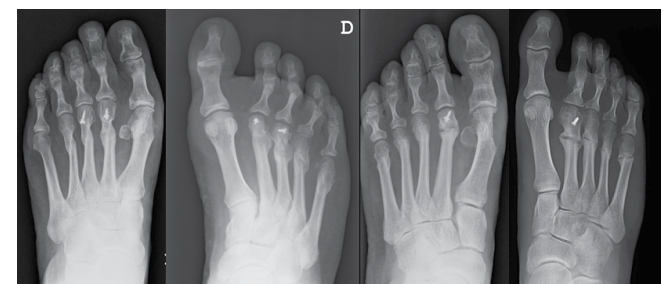
**Figure 1:** Preoperative radiographs of patients with persistent metatarsalgia following open surgery with Weil osteotomies.

(Figure 1). In all cases, salvage surgery consisted in percutaneous distal metatarsal mini-invasive osteotomies (DMMO), with immediate load-bearing using a postoperative shoe with a rigid sole (Figure 2).

At 12 months of follow-up, all patients were satisfied with the outcome, and were able to walk without limitations in distance and with no footwear restrictions (Figure 3).



**Figure 2:** Postoperative radiographs following DMMO.



**Figure 3:** Radiologic follow-up at 6 months shows nearly complete consolidation of all metatarsals.

\*Corresponding author: Dr Xavier Conesa Muñoz, Department of Orthopedic Surgery and Traumatology Hospital Municipal de Badalona, Barcelona, Spain, Tel: +34629009346; E-mail: [xaviconesa@hotmail.com](mailto:xaviconesa@hotmail.com)

Received December 26, 2013; Accepted December 30, 2013; Published January 04, 2013

**Citation:** Conesa X, Ustes X, Parals F, Ribau MA, Via-Dufresne O, et al. (2014) Percutaneous Salvage Surgery for Weil Metatarsal Osteotomies. Clin Res Foot Ankle 2: 125. doi: [10.4172/2329-910X.1000125](https://doi.org/10.4172/2329-910X.1000125)

**Copyright:** © 2014 Conesa X, et al. This is an open-access article distributed under the terms of the Creative Commons Attribution License, which permits unrestricted use, distribution, and reproduction in any medium, provided the original author and source are credited.

## Discussion

The reported midterm outcome of Weil osteotomy is satisfactory, the main complications being “floating toes” and contracture in extension, which are usually well tolerated and do not affect the functional results. Another complication may be a lack of elevation or a drop in the center of rotation of the metatarsal head, which can result in persistence of metatarsal pain [4].

Modification of the original Weil technique by addition of a second osteotomy enables greater elevation of the metatarsal head and a decrease in recurrent metatarsalgia at gait push off [1,3,4]

Percutaneous osteotomy has proven to be a valid technique that yields results similar to open osteotomy for the treatment of hallux valgus and metatarsalgia [5,6]. DMMO enables surgical salvage without the need to remove the screw, by performing the osteotomy at a slightly more proximal position, at the level of the metatarsal neck. Being a minimally invasive procedure, it is associated with a lower risk of dorsiflexion contracture of the toes, which is more common in reinterventions due to the need to act on various metatarsals to achieve a harmonious curve according to the Maestro criteria [6,7].

In conclusion, percutaneous surgery is an effective surgical option for salvage treatment of open Weil osteotomies with screw fixation. The

percutaneous technique does not require removal of the synthesis material, and it is associated with a lower incidence of dorsiflexion contracture of the toes.

## References

1. Hofstaetter SG, Hofstaetter JG, Petroutsas JA, Gruber F, Ritschl P, et al. (2005) The Weil osteotomy: a seven-year follow-up. *J Bone Joint Surg Br* 87: 1507-1511.
2. Espinosa N, Maceira E, Myerson MS (2008) Current concept review: metatarsalgia. *Foot Ankle Int* 29: 871-879.
3. Khurana A, Kadamabande S, James S, Tanaka H, Hariharan K (2011) Weil osteotomy: assessment of medium term results and predictive factors in recurrent metatarsalgia. *Foot Ankle Surg* 17: 150-157.
4. Highlander P, VonHerbulis E, Gonzalez A, Britt J, Buchman J (2011) Complications of the Weil osteotomy. *Foot Ankle Spec* 4: 165-170.
5. AACP, Henry J, Besse JL, Fessy MH (2011) Distal osteotomy of the lateral metatarsals: a series of 72 cases comparing the Weil osteotomy and the DMMO percutaneous osteotomy. *Orthop Traumatol Surg Res* 97: S57-65.
6. García-Fernández D, Gil-Garay E, Lora-Pablos D, De-la-Cruz-Bértolo J, Llanos-Alcázar LF (2011) Comparative study of the Weil osteotomy with and without fixation. *Foot Ankle Surg* 17: 103-107.
7. De Prado M, Ripoll L, Golanó P (2004) *Cirugía percutánea del antepié*. Barcelona, Ed Masson.